

# Chronische venöse Insuffizienz: Bedeutung und Nachweis von Perforansvenen

PD Dr med Rolf Engelberger

HFR Fribourg - Service d'Angiologie

[rolf.engelberger@h-fr.ch](mailto:rolf.engelberger@h-fr.ch)

# Superziel des Vortrags

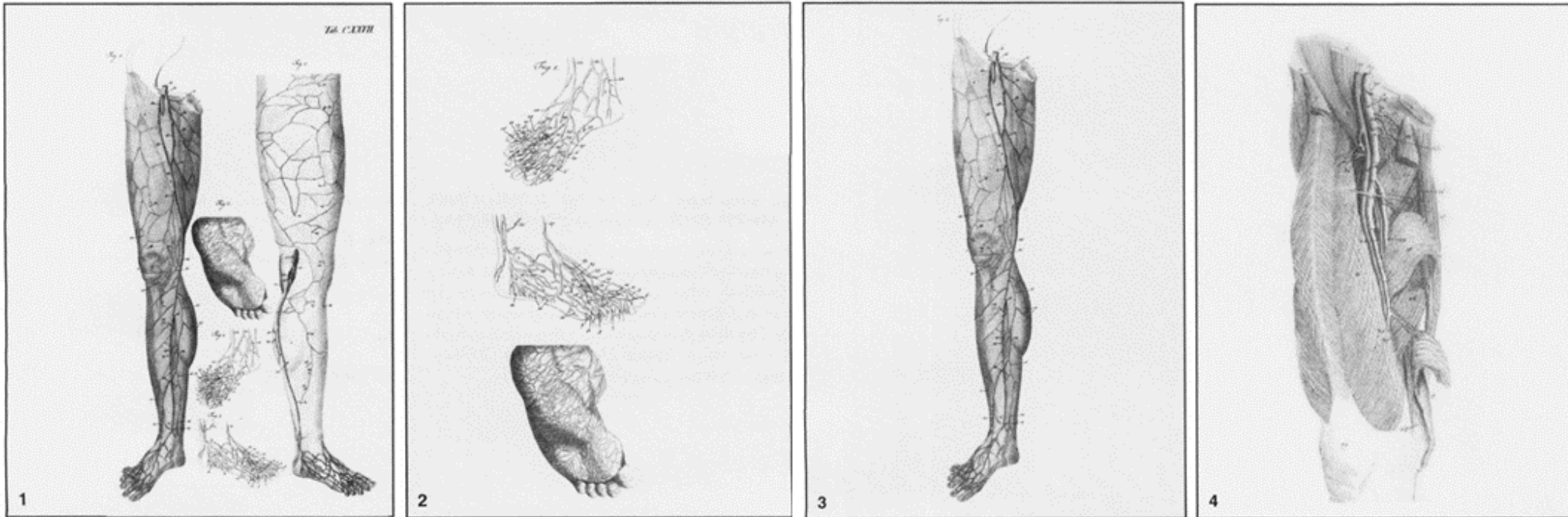


Image téléchargé de <https://www.mycomicshop.com/search?ItemID=58279353>

## Historical Notes

### The Discovery of Perforating Veins

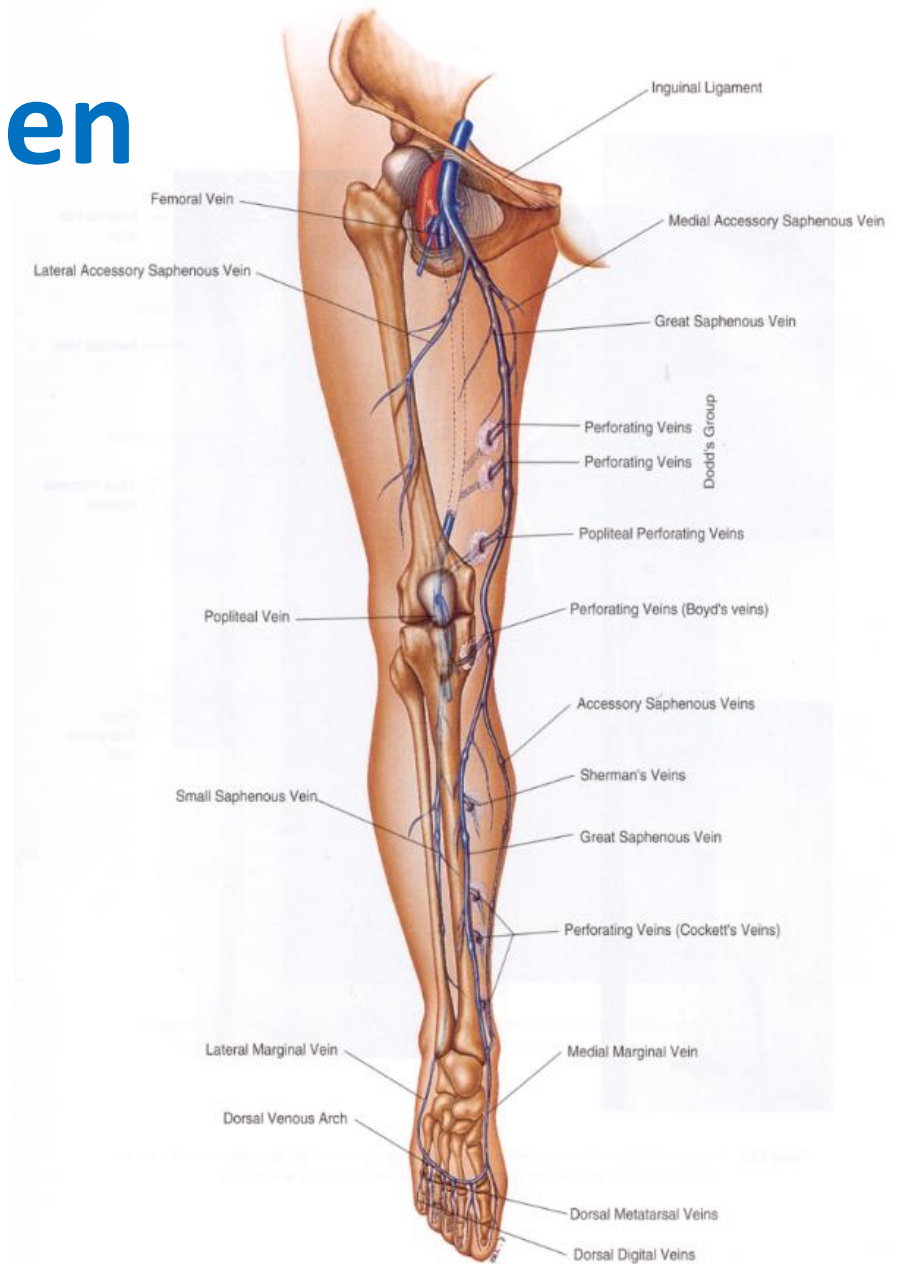
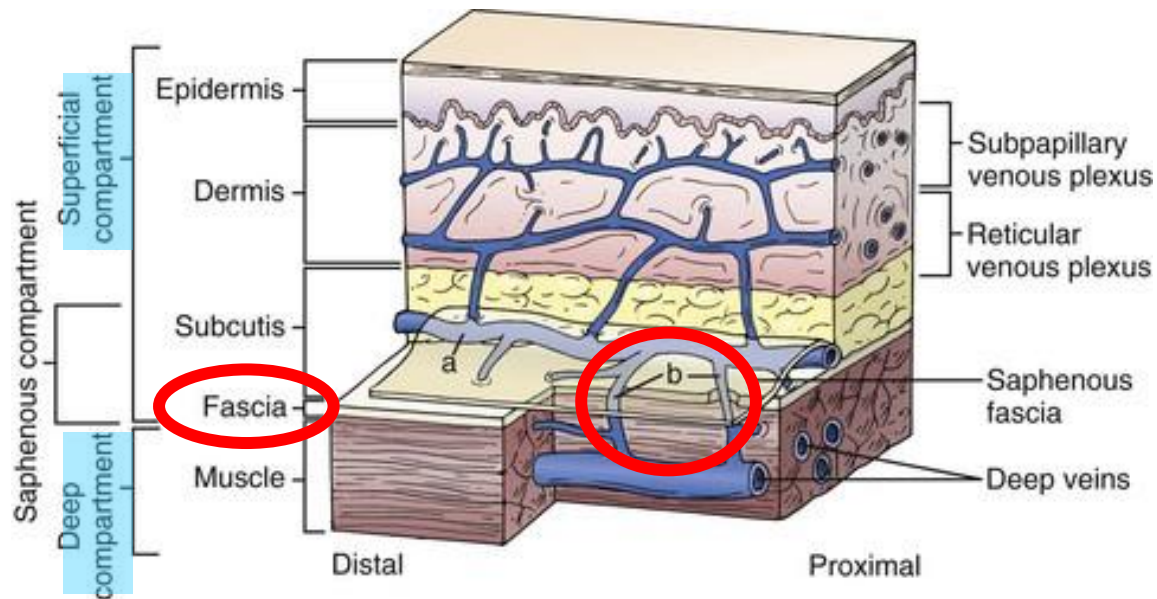
- PV first reported in the *Anatomische Tafeln zur Beforderung der Kenntniss des menschlichen Körpers* (Weimar, 1794-1803), the main work of the German anatomist, **Justus Christian Von Loder** (1753-1832), from Riga.
- Von Loder named them "**communicating**" veins ("*rami communicantes cum profundibus venis*")
  - the term "perforating veins" was used only to indicate the foot PV ("*venae perforantes*") and the roots of the deep femoral vein ("*vena perforans magna prima*")



# Anatomie der Perforansvenen

**Definition:** Perforansvenen (PV) verbinden die oberflächlichen mit den tiefen Venen, und verlaufen durch die Muskelfaszie.

PV sind zahlreich und sehr variabel in Verteilung, Verbindung und Größe



# Bezeichnung der Perforansvenen «früher»

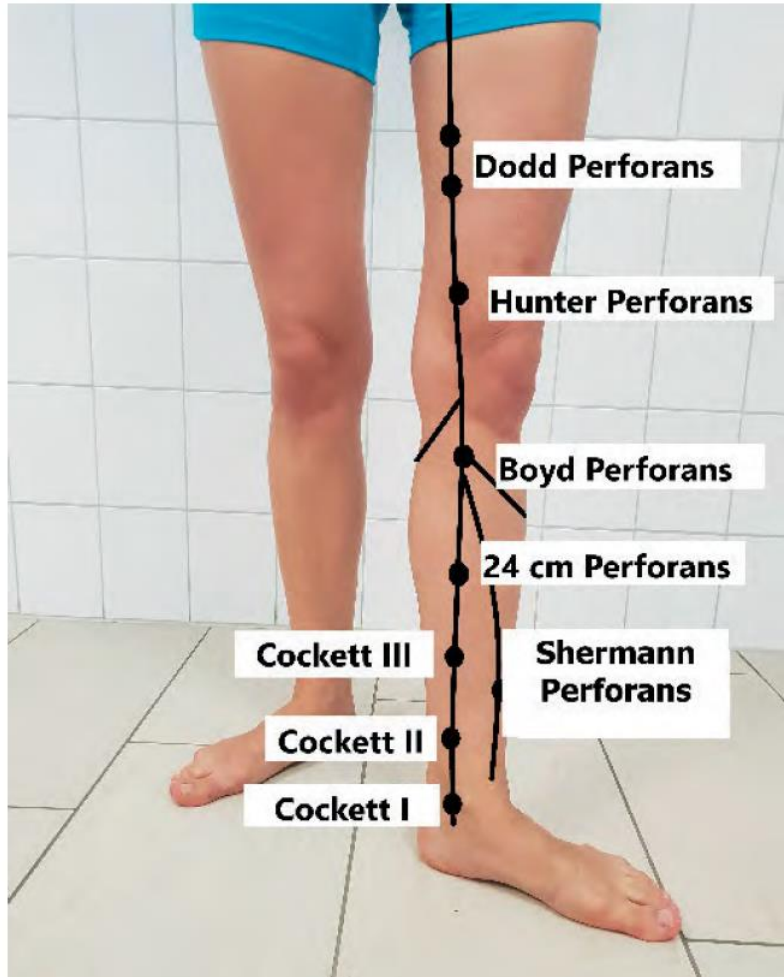


Abb. 2 Lokalisation der bekanntesten Perforansvenen von ventral

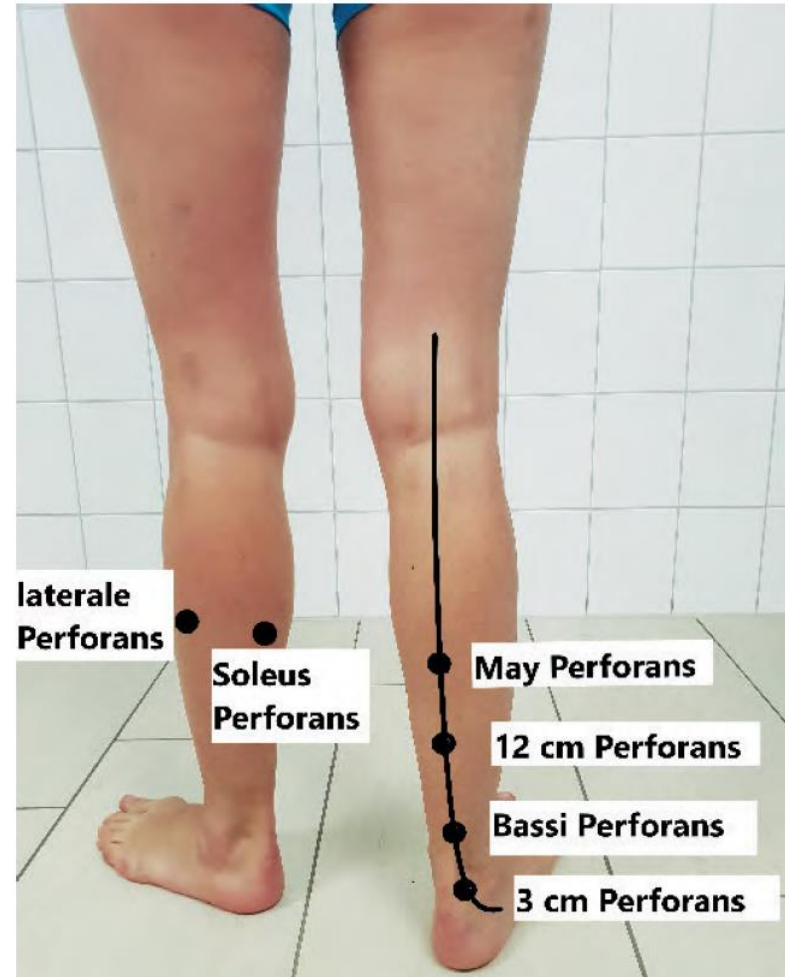


Abb. 3 Lokalisation der Perforansvenen von dorsal

# Bezeichnung der Perforansvenen «heute»

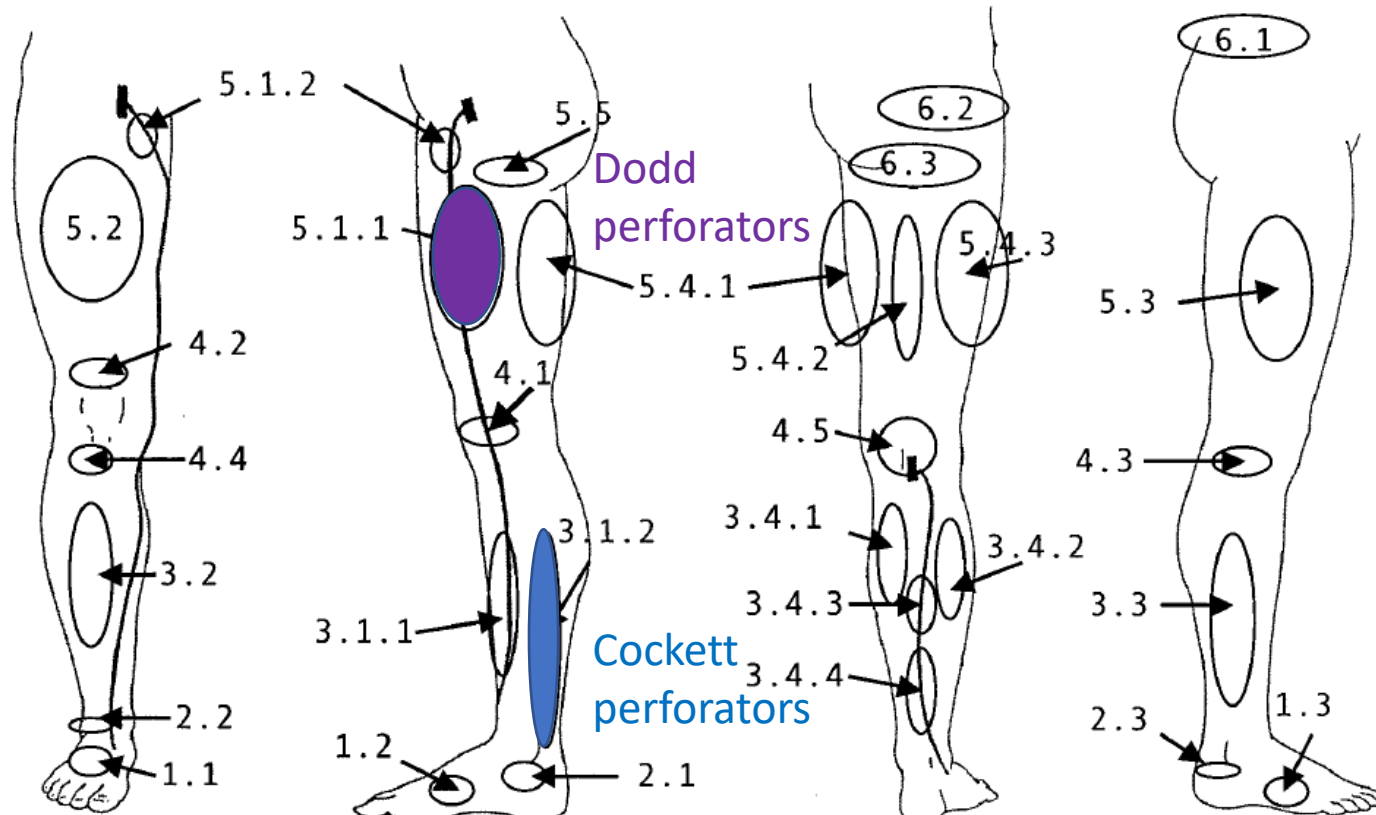
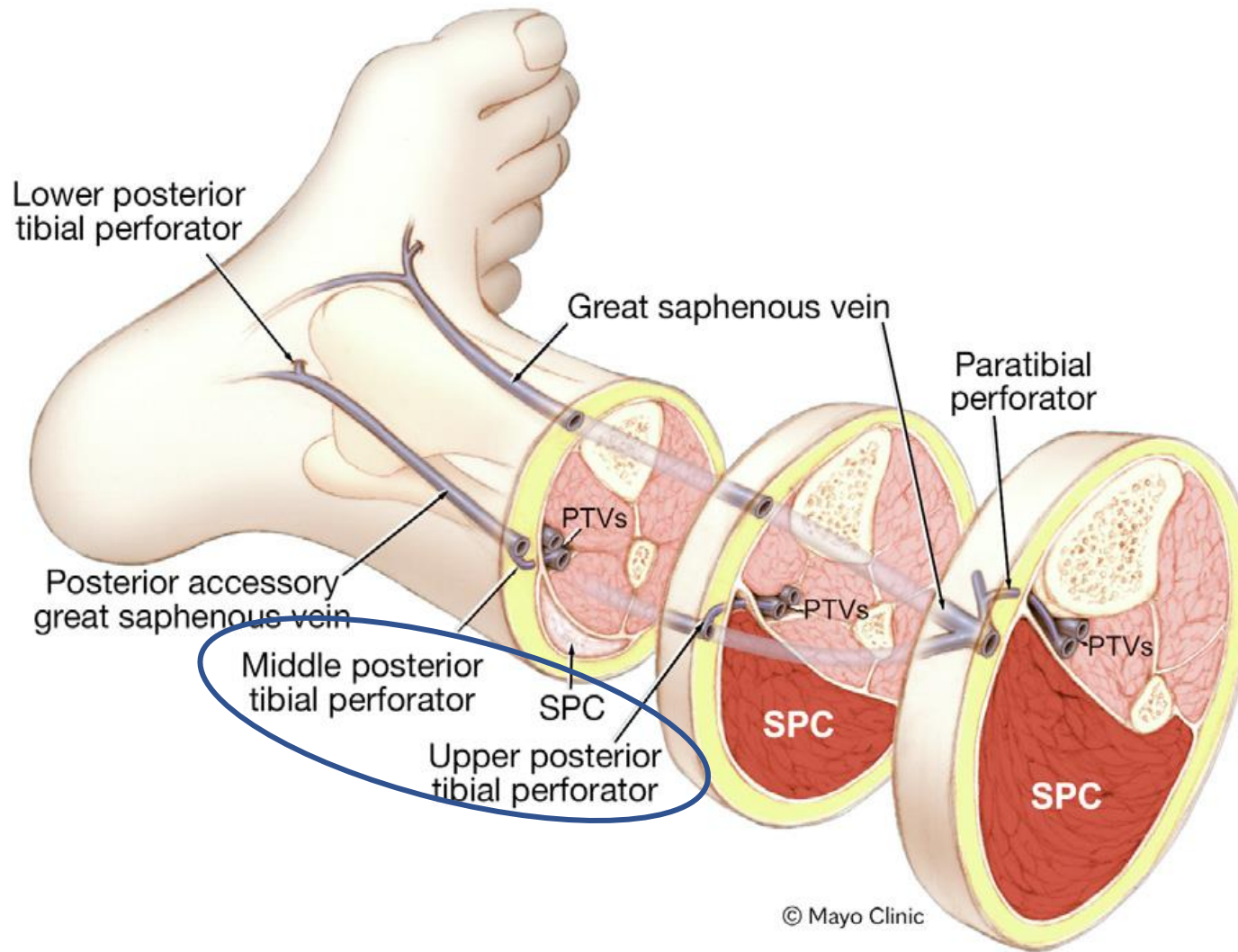


Fig 5. Schematic representation of the topography of the main groups of perforating veins (PVs). Foot PVs: 1.1, dorsal foot PV; 1.2, medial foot PV; 1.3, lateral foot PV. Ankle PVs: 2.1, medial ankle PV; 2.2, anterior ankle PV; 2.3, lateral ankle PV. Leg PVs: 3.1.1, paratibial PV; 3.1.2, posterior tibial PV; 3.2, anterior leg PV; 3.3, lateral leg PV; 3.4.1, medial gastrocnemius PV; 3.4.2, lateral gastrocnemius PV; 3.4.3, intergemellar PV; 3.4.4, para-achillean PV. Knee PVs: 4.1, medial knee PV; 4.2, suprapatellar PV; 4.3, lateral knee PV; 4.4, infrapatellar PV; 4.5, popliteal fossa PV. Thigh PVs: 5.1.1, PV of the femoral canal; 5.1.2, inguinal PV; 5.2, anterior thigh PV; 5.3, lateral thigh PV; 5.4.1, posteromedial thigh PV; 5.4.2, sciatic PV; 5.4.3, posterolateral thigh PV; 5.5, pudendal PV. Gluteal PVs: 6.1, superior gluteal PV; 6.2, midgluteal PV; 6.3, lower gluteal PV.

Table III. Perforating veins

Main groups	Subgroups
Foot perforators	Dorsal foot pv or intercapitular veins Medial foot PV Lateral foot PV Plantar foot PV
Ankle perforators	Medial ankle PV Anterior ankle PV Lateral ankle PV
Leg perforators	Medial leg PV Paratibial PV Posterior tibial PV Anterior leg PV Lateral leg PV Posterior leg PV Medial gastrocnemius PV Lateral gastrocnemius PV Intergemellar PV Para-achillean PV
Knee perforators	Medial knee PV Suprapatellar PV Lateral knee PV Infrapatellar PV Popliteal fossa PV
Thigh perforators	Medial thigh PV PV of the femoral canal Inguinal PV Anterior thigh PV Lateral thigh PV Posterior thigh PV
Gluteal perforators	Posteromedial Sciatic PV Posterolateral Pudendal PV Superior gluteal PV Midgluteal PV Lower gluteal PV

# Bezeichnung der Perforansvenen «heute»



© Mayo Clinic

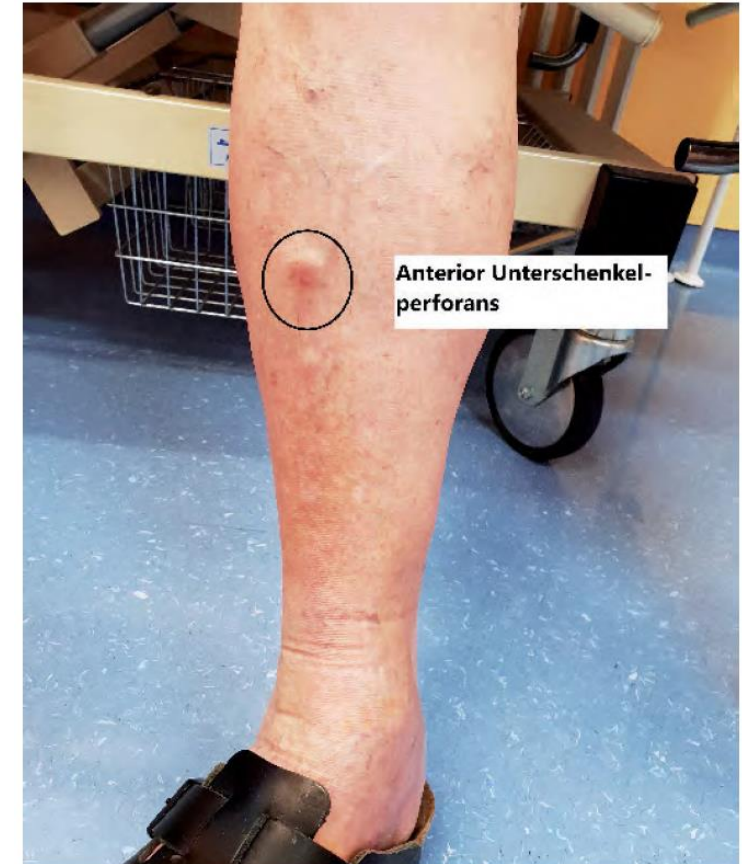Table III. Perforating veins

Main groups	Subgroups
Foot perforators	Dorsal foot pv or intercapitular veins Medial foot PV Lateral foot PV Plantar foot PV
Ankle perforators	Medial ankle PV Anterior ankle PV Lateral ankle PV
Leg perforators	Medial leg PV Paratibial PV Posterior tibial PV Anterior leg PV Lateral leg PV Posterior leg PV Medial gastrocnemius PV Lateral gastrocnemius PV Intergemellar PV Para-achillean PV
Knee perforators	Medial knee PV Suprapatellar PV Lateral knee PV Infrapatellar PV Popliteal fossa PV
Thigh perforators	Medial thigh PV PV of the femoral canal Inguinal PV Anterior thigh PV Lateral thigh PV Posterior thigh PV Posteromedial Sciatic PV Posterolateral
Gluteal perforators	Pudendal PV Superior gluteal PV Midgluteal PV Lower gluteal PV

# Klinik der Perforans-Insuffizienz

Erweiterte insuffiziente PV können zu pathologisch **erweiterten Faszienlücken** führen (bei Palpation häufig schmerzhaft)

Bei stehendem Patienten können insuffiziente PV teils durch das sog. **Blow-Out-Phänomen** auffallen



**Abb. 4** Paratibiale Perforansvene nach traumatischer Verletzung der Tibia mit typischem Blow-out-Phänomen

# UIP Consensus Document



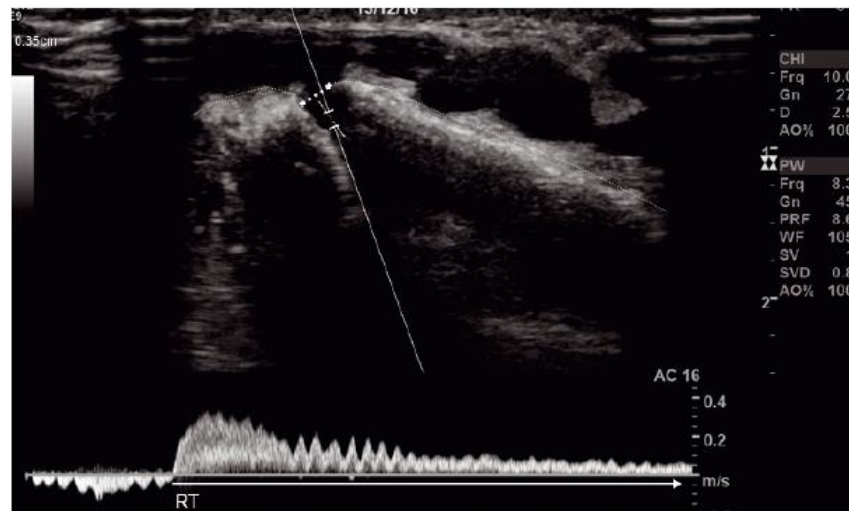
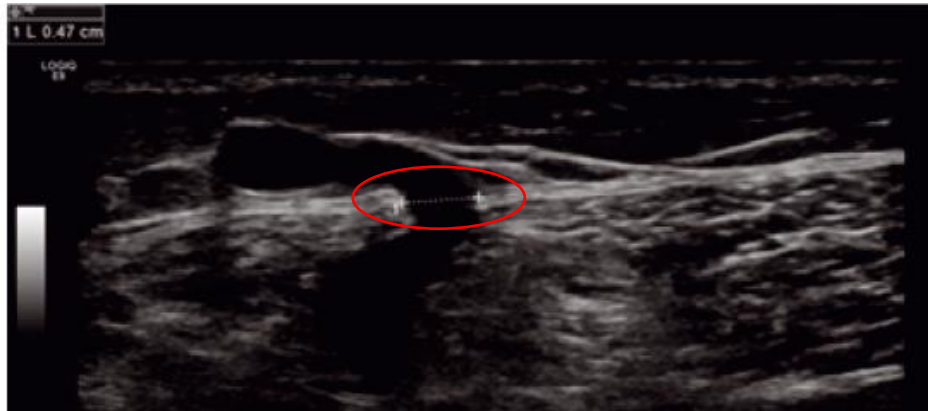
Union Internationale  
de Phlébologie

International Union of Phlebology

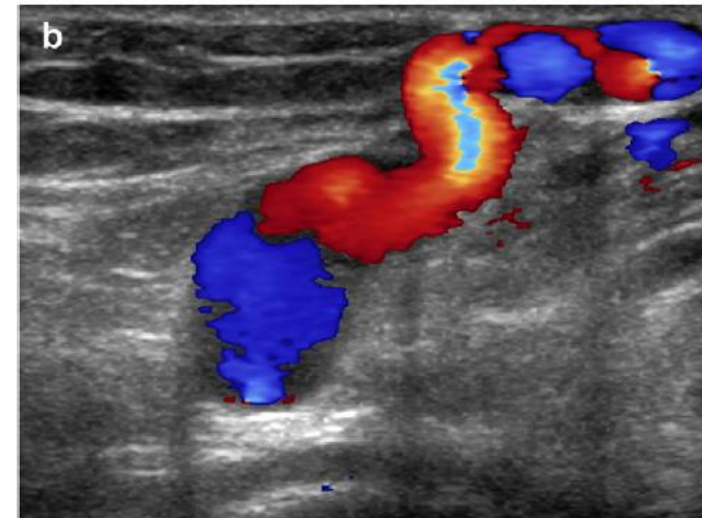
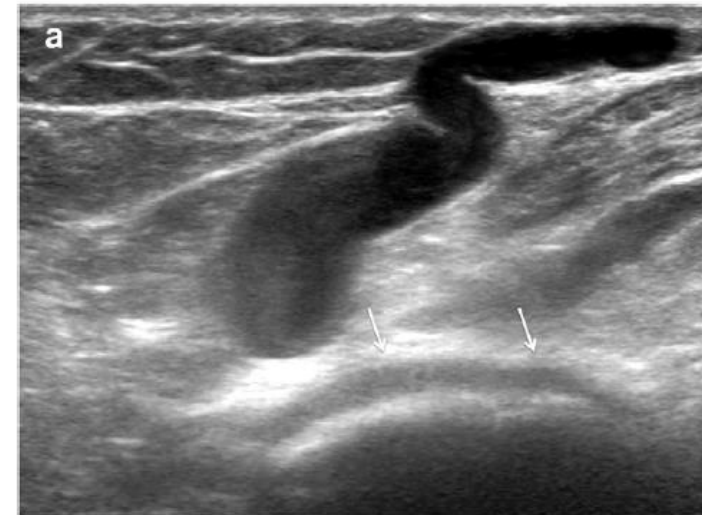## Preoperativer Venenduplex

1. Tiefes Venensystem	<ol style="list-style-type: none"><li>1. <i>Deep veins</i>: assessment for patency and reflux<ul style="list-style-type: none"><li>- common femoral vein (CFV)</li><li>- popliteal vein</li></ul></li></ol>
2./3. Hauptstämme	<ol style="list-style-type: none"><li>2. <i>Junctions</i>: assessment for reflux (terminal valve/pre-terminal valve)<ul style="list-style-type: none"><li>- saphenofemoral junction (SFJ)</li><li>- saphenopopliteal junction (SPJ)</li></ul></li><li>3. <i>Main trunks</i>: diameter measurement and assessment of reflux (in the saphenous compartment):<ul style="list-style-type: none"><li>- great saphenous vein (GSV)</li><li>- anterior accessory saphenous vein (AASV)</li><li>- posterior accessory saphenous vein (PASV)</li><li>- small saphenous vein (SSV)</li><li>- thigh extension of SSV/Giacomini vein</li></ul></li></ol>
4./5. Saphena- und nicht-Saphena-Seitenäste	<ol style="list-style-type: none"><li>4. <i>Tributaries</i>: if incompetent</li><li>5. <i>Non-saphenous veins</i>: if incompetent</li></ol>
6. Perforansvenen	<ol style="list-style-type: none"><li>6. <i>Perforating veins</i>: diameter measurement and assessment of reflux</li></ol>

# Perforansvenen im Duplex

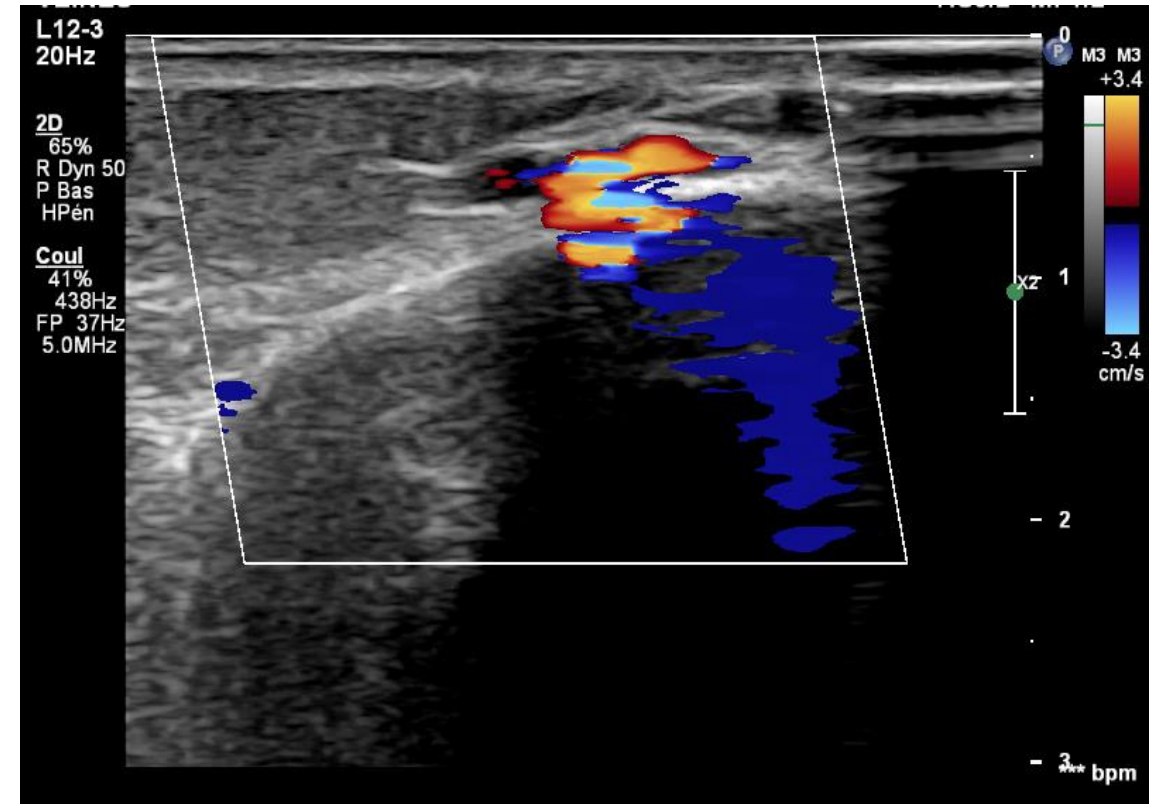
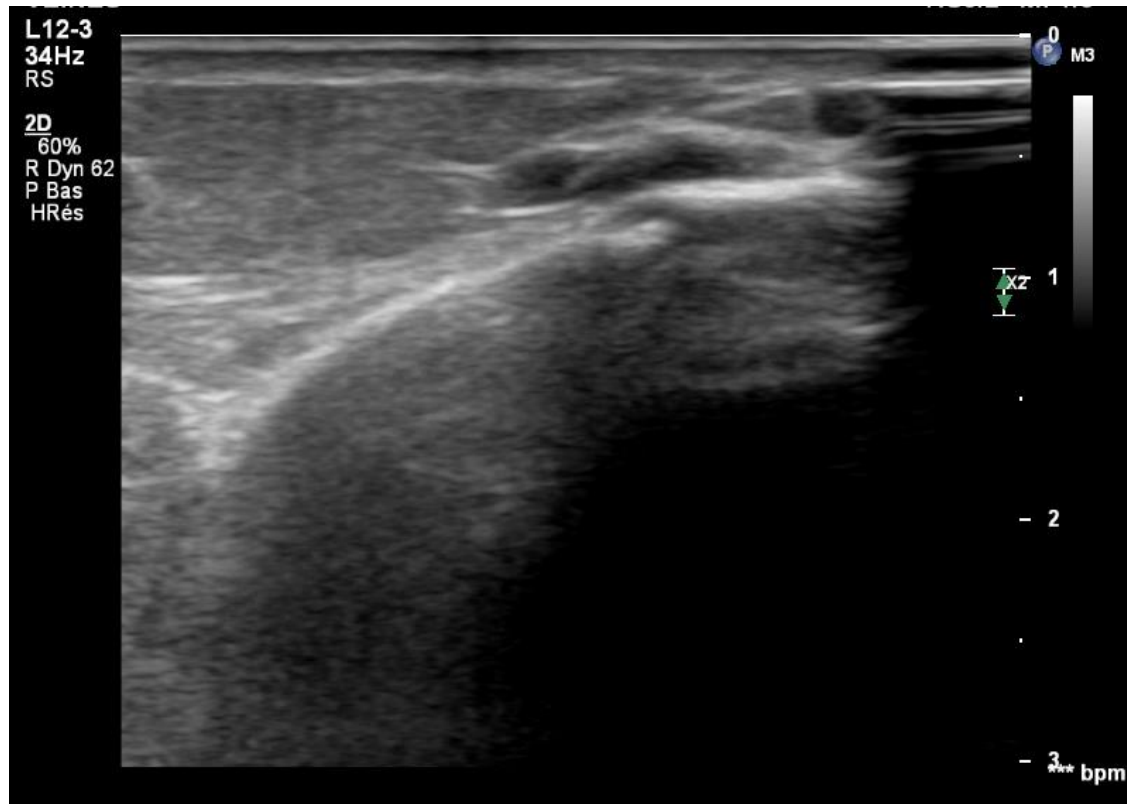


**Figure 8.** Intraosseous perforating vein penetrating in the tibia (dotted line) at mid-calf with a diameter of 3.5 mm and a longstanding reflux time (RT).



**Figure 4** (a) A popliteal fossa perforating vein can be recognised from its typical location in front of the lateral condyle of the femur (arrows). (b) Colour duplex image shows reflux in this tortuous vein.

# Intraosseous perforating vein



# Perforansvenen-Insuffizienz im Duplex

**PV normalerweise Flussrichtung:**

➤ **oberflächliches → tiefes Venensystem**

## Reflux-Testung ?

- Manuelles Kompressionsmanöver ist unphysiologisch, bei Zusammendrücken des schlaffen Muskels können in der dadurch gedehnten PV Blutflüsse auftreten, die bei der physiologischen Muskelkontraktion nicht auftreten würden, da die aktive Muskulatur die PV verschließen würde
- Pathologische Signifikanz eines Bidirektionellen Flusses in der PV ist umstritten

# Medial calf perforators in venous disease: The significance of outward flow

Sanjeev Sarin, FRCS, John H. Scurr, FRCS, and Philip D. Coleridge Smith, FRCS,  
*London, England*

## Method:

- Mittels Farbdoppler Flussrichtung in medialen Unterschenkel PV getestet
- Standardisiertes Kompressionsmanöver distal (am Fuss) oder proximal (proximaler Unterschenkel) der PV
- Studienprobanden: total 57 Probanden → 114 Beine

Normal (keine SVI oder DVI)

+/- venöse Erkrankung am anderen Bein (CVD)

Oberflächliche Veneninsuffizienz (SVI)

+/- Lipodermatosklerose (LDS)

Tiefe Veneninsuffizienz (DVI)

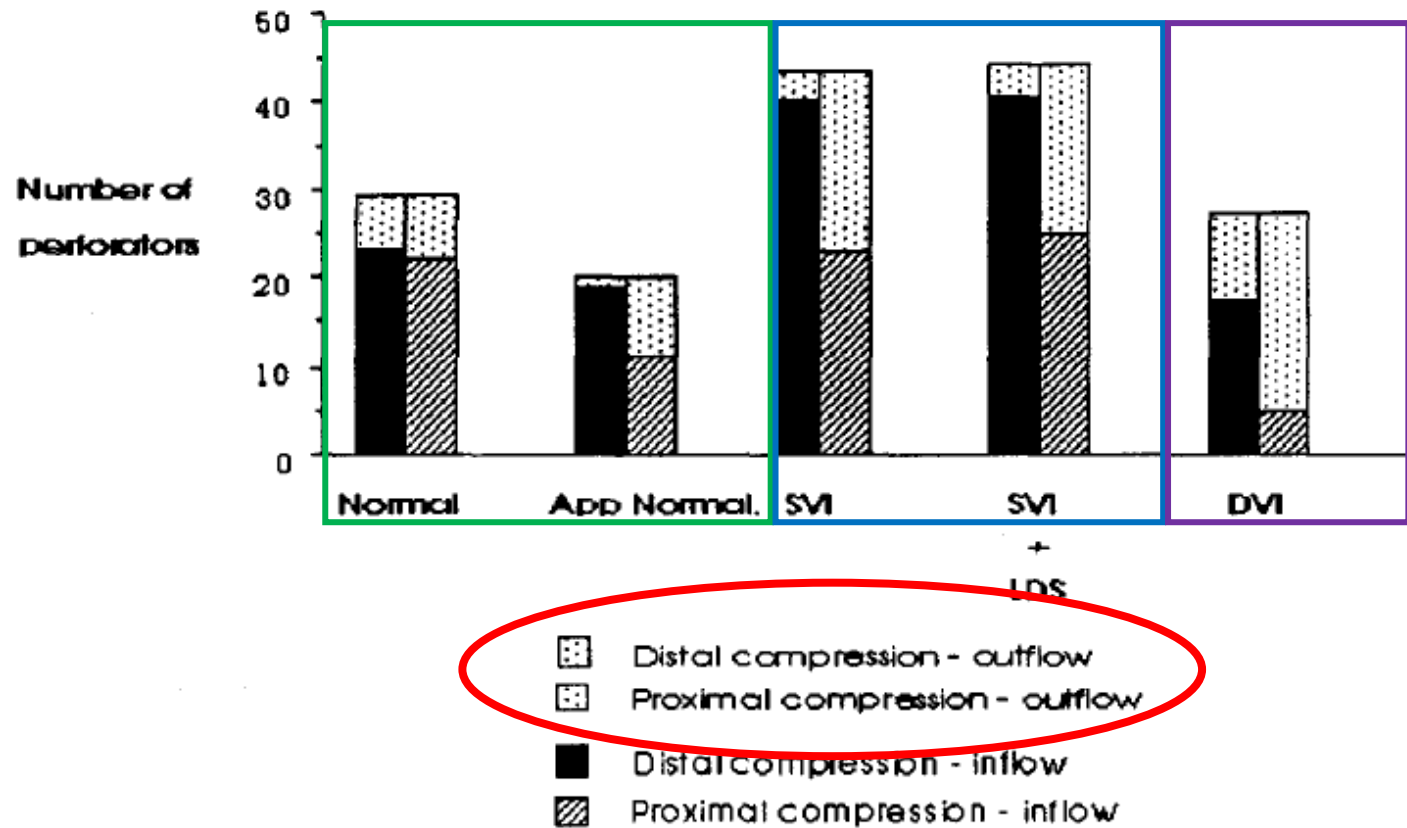
**Table I.** Age distribution of patients

<i>Abnormality</i>	<i>No. of patients</i>	<i>No. of limbs</i>	<i>Median age (interquartile range) yr</i>
All patients	57	114	56 (40-62)
Normal	10	20	45 (33-56)
Normal- (CVD)	19	19	51 (40-59)
SVI	22	31	57 (38-63)
SVI + LDS	17	29	57 (52-65)
DVI	8	15	57 (48-70)

*CVD*, Contralateral venous disease; *LDS*, lipoderm atosclerosis.

# Medial calf perforators in venous disease: The significance of outward flow

Sanjeev Sarin, FRCS, John H. Scurr, FRCS, and Philip D. Coleridge Smith, FRCS,  
*London, England*



# Medial calf perforators in venous disease: The significance of outward flow

Sanjeev Sarin, FRCS, John H. Scurr, FRCS, and Philip D. Coleridge Smith, FRCS,  
London, England

**Table II.** Direction of blood flow within perforators

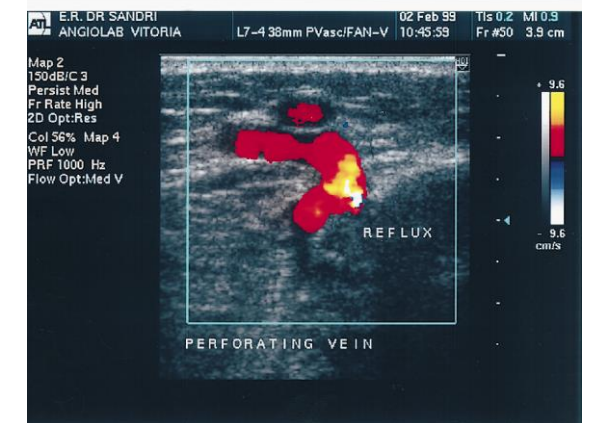
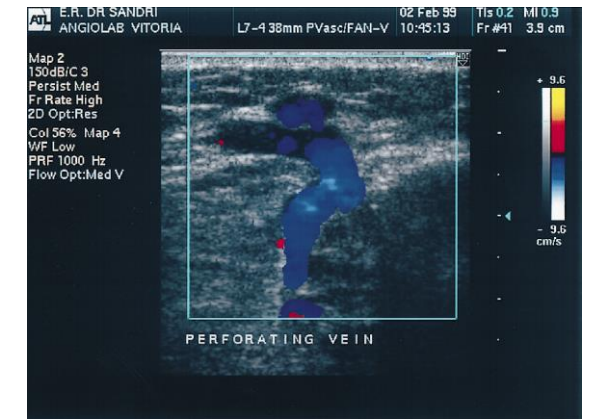
<i>Abnormality</i> (No. of perforators)	<i>Compression phase</i>			<i>Relaxation phase</i>	
	<i>Inflow</i>	<i>Outflow</i>		<i>Inflow</i>	<i>Outflow</i>
<b>Distale Kompression</b>					
<i>Distal compression</i>					
Normal (29)	23 (79%)	6 (21%)		0 (0%)	0 (0%)
Normal-CVD (20)	19 (95%)	1 (5%)		$\chi^2 = 1.2$ NS	0 (0%)
SVI (43)	40 (93%)	3 (7%)	]	8 (19%)	6 (14%)
SVI + LDS (44)	40 (91%)	4 (9%)		$\chi^2 = 1.8$ NS	8 (18%)
DVI (27)	17 (63%)	10 (37%)	]	6 (22%)	6 (22%)
			$\chi^2 = 1.1$ NS		
<b>Proximale Kompression</b>					
<i>Proximal compression</i>					
Normal (29)	22 (76%)	7 (24%)		3 (10%)	9 (31%)
Normal- CVD (20)	11 (55%)	9 (45%)		4 (20%)	3 (15%)
SVI (43)	23 (54%)	20 (46%)		11 (26%)	11 (26%)
SVI + LDS (44)	25 (57%)	19 (43%)		15 (34%)	3 (7%)
DVI (27)	5 (19%)	22 (81%)		14 (52%)	7 (26%)

# Diameter-reflux relationship in perforating veins of patients with varicose veins

João Luis Sandri, MD, Fanilda S. Barros, MD, Sandra Pontes, MD, Claudio Jacques, MD, and Sergio X. Salles-Cunha, PhD, *Vitoria, Espirito Santo, Brazil*

## Method:

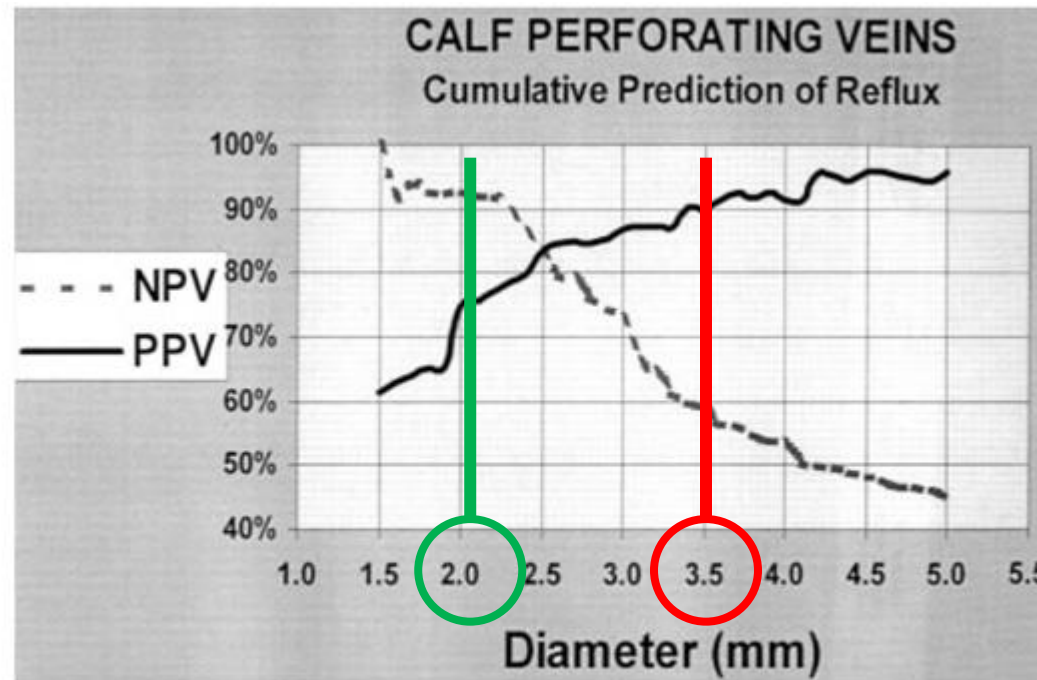
- Duplexuntersuchung von 500 Perforansvenen (insgesamt 78 Patienten CEAP C<sub>2</sub> und C<sub>3</sub>)
- Untersuchung von PV am Ober- und Unterschenkel
  - Messung **Durchmesser am Faszienübertritt**
  - **Refluxmessung** mit proximalem und distalem manuellem Kompressionsmanöver ( $\geq 0,5$ sek pathologisch)
    - 282 (56%) insuffiziente PV



# Diameter-reflux relationship in perforating veins of patients with varicose veins

João Luis Sandri, MD, Fanilda S. Barros, MD, Sandra Pontes, MD, Claudio Jacques, MD, and Sergio X. Salles-Cunha, PhD, *Vitoria, Espirito Santo, Brazil*

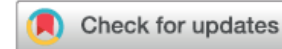Durchmesser von  $\leq 2,2\text{mm}$  prädiktiv für keinen Reflux in 92% der Fälle (NPV)



Durchmesser von  $\geq 3,5\text{mm}$  prädiktiv für Reflux in 90% der Fälle (PPV)

Fig 2. Cumulative predictive values for reflux in calf perforating veins. Cumulative negative- and positive-predictive values were calculated for diameters smaller than or larger than that plotted at the horizontal axis, respectively. *NPV*, negative-predictive value; *PPV*, positive predictive value.

# SOCIETY FOR VASCULAR SURGERY GUIDELINES



The 2022 Society for Vascular Surgery, American Venous Forum, and American Vein and Lymphatic Society clinical practice guidelines for the management of varicose veins of the lower extremities. Part I. Duplex Scanning and Treatment of Superficial Truncal Reflux

*Endorsed by the Society for Vascular Medicine and the International Union of Phlebology*

1.1.c. A definition of “pathologic” perforating veins in patients with varicose veins (CEAP [Clinical Class, Etiology, Anatomy, Pathology] clinical class C2) includes those with an outward flow duration of  $\geq 500$  ms and a diameter of  $\geq 3.5$  mm on duplex ultrasound.

# Duplex Ultrasound Investigation of the Veins in Chronic Venous Disease of the Lower Limbs—UIP Consensus Document. Part I. Basic Principles

... some authors argue that true **pathological incompetence** is present only if **reflux is elicited during the diastolic phase** of calf muscle relaxation or release of compression.

Accordingly, some authors suggest testing for **inward and outward flow separately** during calf muscle contraction or compression and calf muscle relaxation or release to help **distinguish pathological from re-entry perforators**



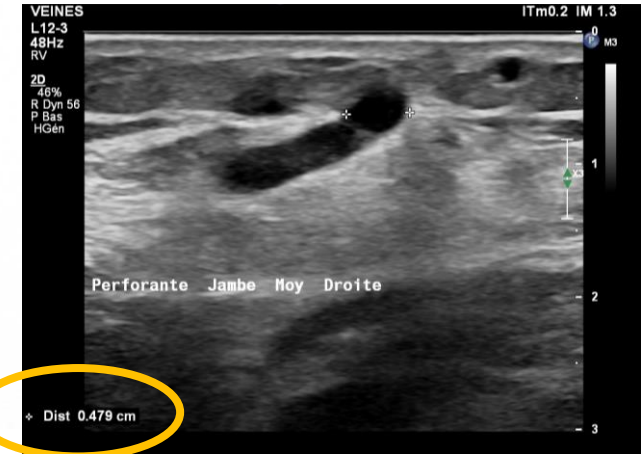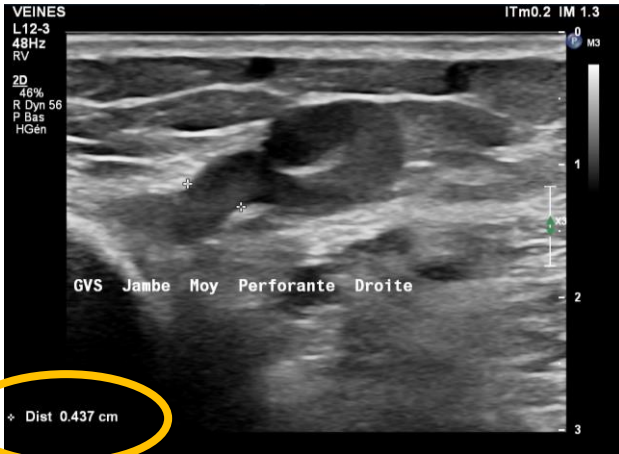
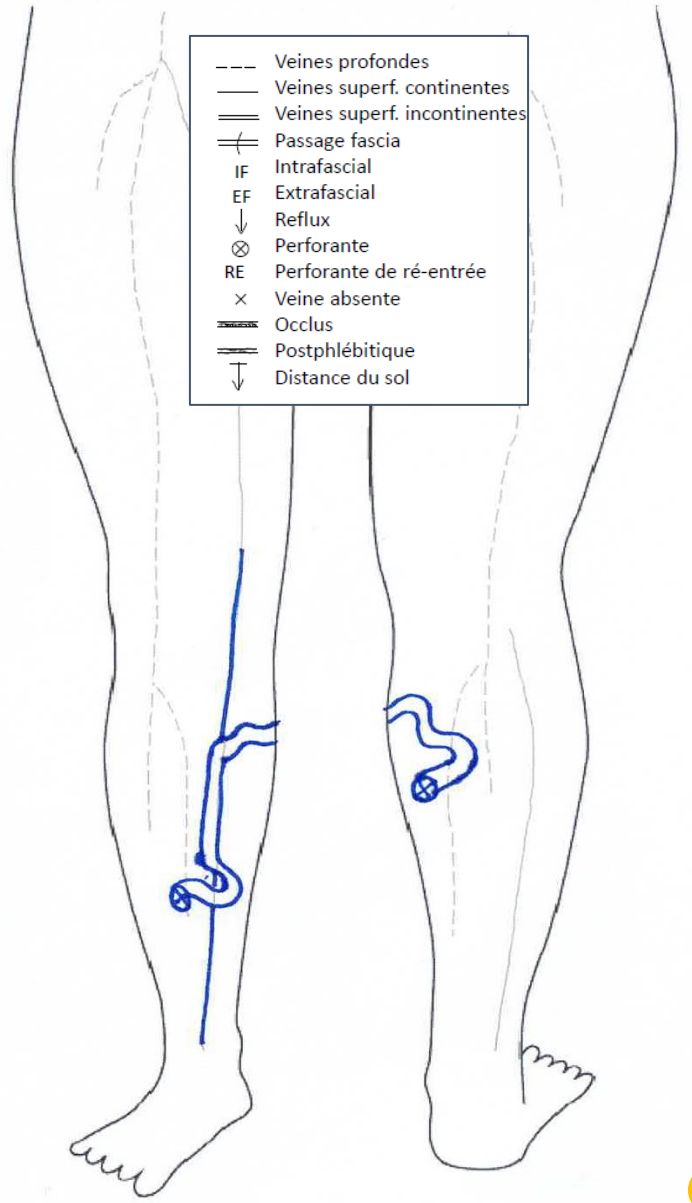
**Union Internationale  
de Phlébologie**

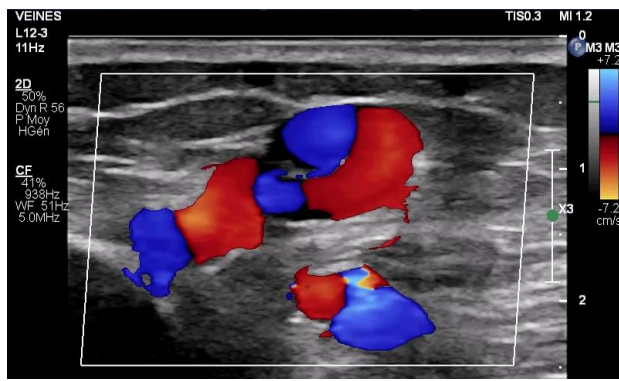
International Union of Phlebology



Ant                      MI droit                      Post

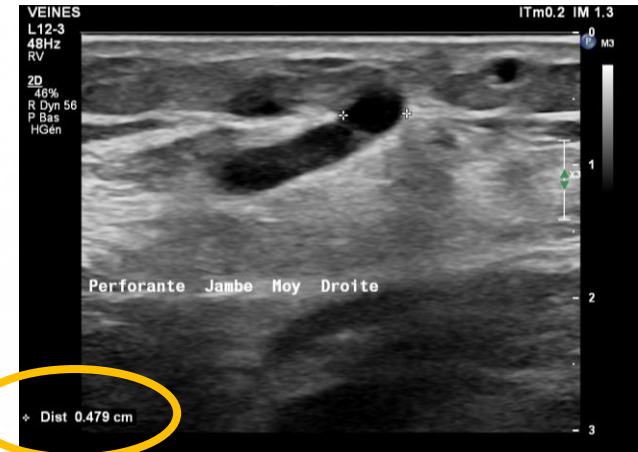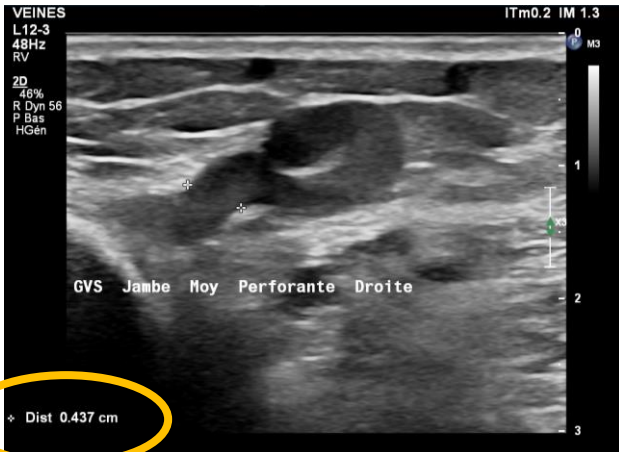
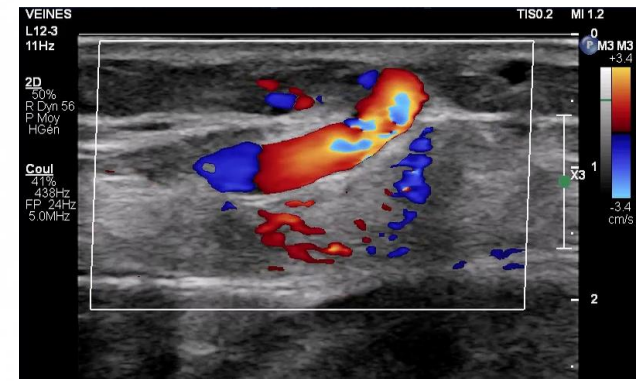
- Veines profondes
- Veines superf. continentes
- == Veines superf. incontinentes
- ⊢ Passage fascia
- IF Intrafascial
- EF Extrafascial
- ↓ Reflux
- ⊗ Perforante
- RE Perforante de ré-entrée
- × Veine absente
- ⊢ Occlus
- ⊢ Postphlébitique
- ↓ Distance du sol

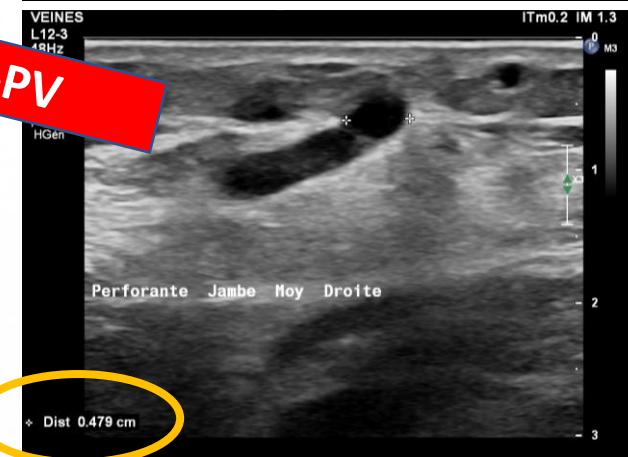
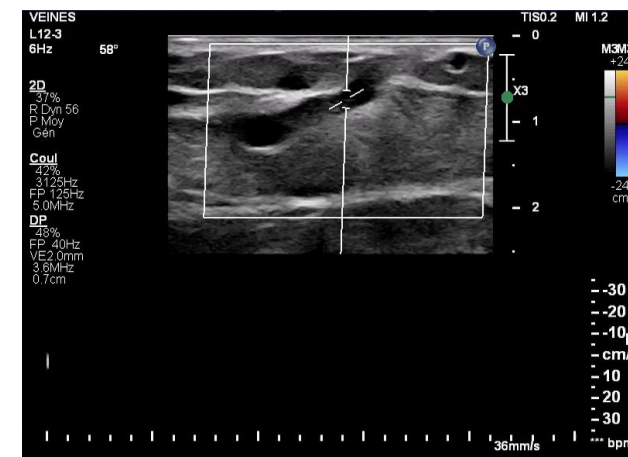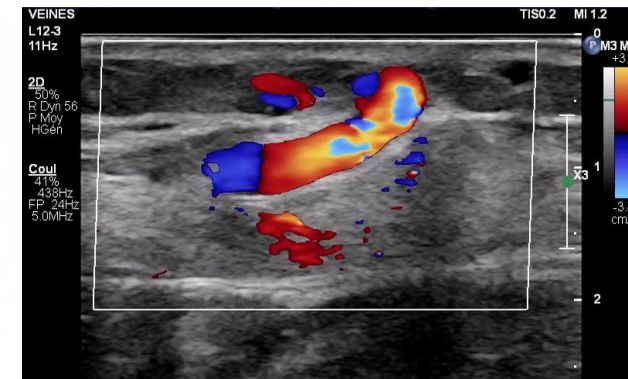
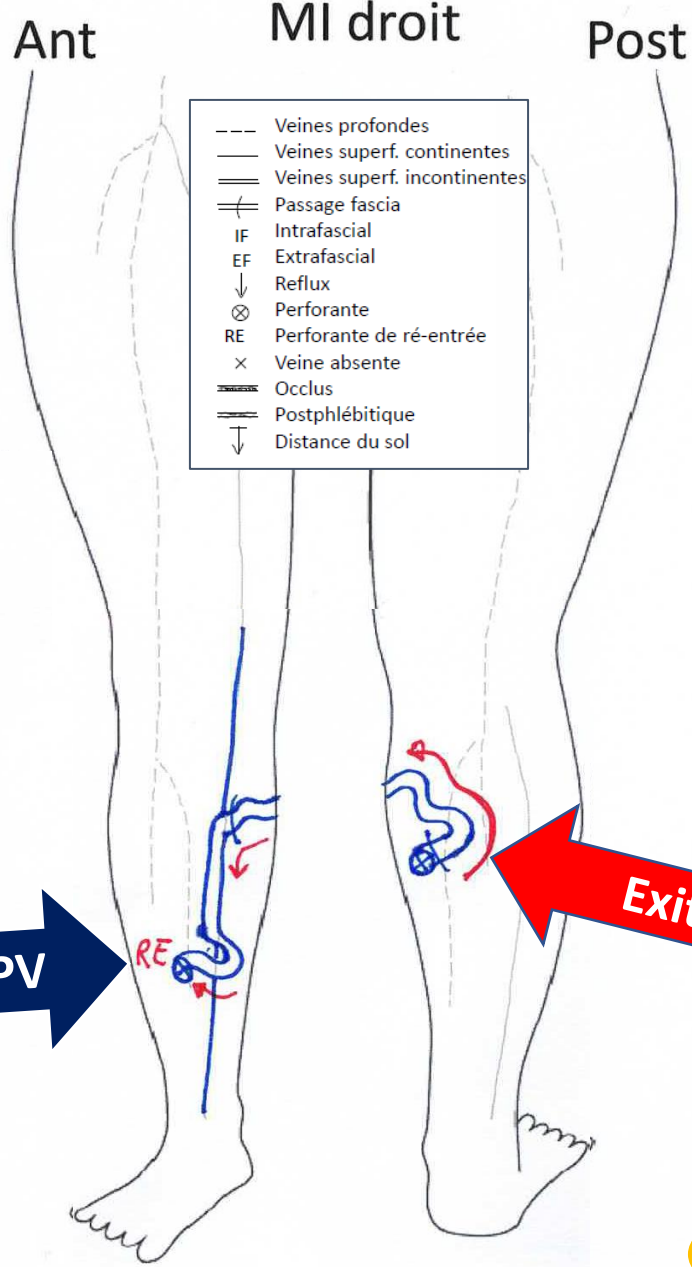
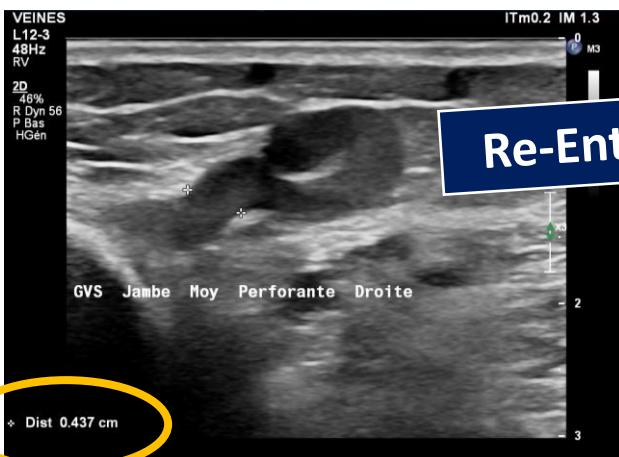
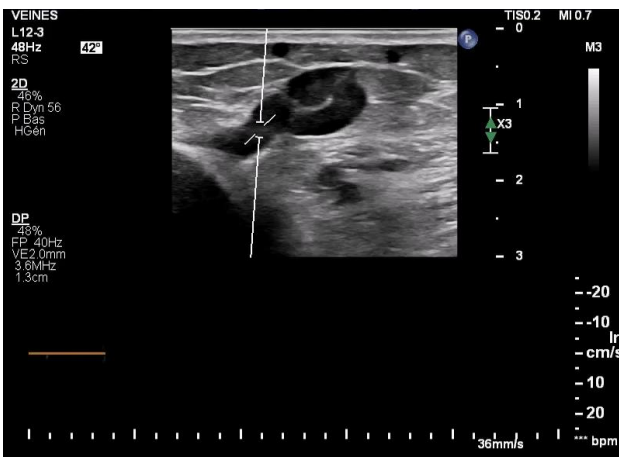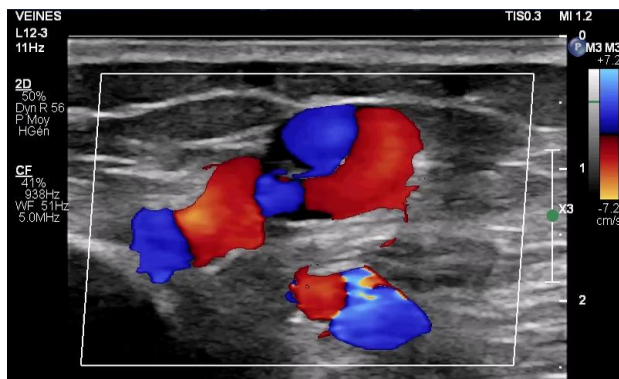




Ant MI droit Post

- Veines profondes
- Veines superf. continentes
- ≡ Veines superf. incontinentes
- ≡ Passage fascia
- IF Intrafascial
- EF Extrafascial
- ↓ Reflux
- ⊗ Perforante
- RE Perforante de ré-entrée
- × Veine absente
- ≡ Occlus
- ≡ Postphlébitique
- ↓ Distance du sol





## APPROPRIATE USE CRITERIA

The 2020 appropriate use criteria for chronic lower extremity venous disease of the American Venous Forum, the Society for Vascular Surgery, the American Vein and Lymphatic Society, and the Society of Interventional Radiology

**Table III.** Appropriateness rating scale

Rating	Explanation
7, 8, 9	Appropriate Treatment is a generally acceptable and reasonable approach for the indication. <i>and</i> Treatment is likely to improve the patient's health outcomes or survival.
4, 5, 6	May be appropriate Treatment may be an acceptable or reasonable approach for the indication. <i>or</i> Treatment may improve the patient's health outcomes or survival. <i>or</i> More research or patient information is necessary to classify the appropriateness of the indication.
2, 3	Rarely appropriate Treatment is not a generally acceptable or reasonable approach for the indication. <i>and</i> Treatment lacks clear benefit/risk advantage. <i>and</i> Treatment is rarely effective for the indication.
1	Never appropriate

## APPROPRIATE USE CRITERIA

# In welchen Situationen ist die Behandlung insuffizienten Perforansvenen sinnvoll ?

**Table XI.** Appropriateness criteria for managing perforators

	Asymptomatic			Symptomatic				
	C <sub>1</sub>	C <sub>2</sub>	C <sub>3</sub>	C <sub>1</sub>	C <sub>2</sub>	C <sub>3</sub>	C <sub>4-6</sub>	
Perforator vein ablation or interruption with high outward flow and large diameter directed toward affected area								
18. Calf perforator vein	Never appropriate Median: 1	Never appropriate Median: 1	Rarely appropriate Median: 1	Rarely appropriate Median: 1	Rarely appropriate Median: 2.5	May be appropriate Median: 4	Appropriate Median: 7	
19. Thigh perforator communicating with incompetent GSV below a competent or interrupted SFJ	Never appropriate Median: 1	Never appropriate Median: 1	Rarely appropriate Median: 1	Rarely appropriate Median: 1	Rarely appropriate Median: 3	May be appropriate Median: 4.5	Appropriate Median: 7	

# Falls dann wie behandeln?

## Editor's Choice – European Society for Vascular Surgery (ESVS) 2022 Clinical Practice Guidelines on the Management of Chronic Venous Disease of the Lower Limbs★

Recommendation 37 <span style="float: right;">New</span>			
For patients with chronic venous disease requiring treatment of incompetent perforating veins, <u>endovenous ablation, division or ligation</u> should be considered.			
Class	Level	References	ToE
Ila	C	Abdul-Haqq <i>et al.</i> (2013), <sup>253</sup> Kiguchi <i>et al.</i> (2014), <sup>263</sup> van Gent <i>et al.</i> (2015), <sup>254</sup> Gibson <i>et al.</i> (2020) <sup>216</sup>	

Recommendation 49 <span style="float: right;">New</span>		
For most patients with varicose veins, <u>without skin changes</u> related to chronic venous disease, <u>treatment of incompetent lower leg perforating veins is not recommended.</u>		
Class	Level	References
III	C	Consensus

Recommendation 50 <span style="float: right;">New</span>			
For patients with <u>advanced skin changes</u> (CEAP clinical class C4b, C5 or C6), with <u>isolated or residual incompetent perforating veins</u> , thought to be significant, treatment may be considered.			
Class	Level	References	ToE
IIf	C	Abdul-Haqq <i>et al.</i> (2013), <sup>253</sup> Kiguchi <i>et al.</i> (2014), <sup>263</sup> van Gent <i>et al.</i> (2015), <sup>254</sup> Gibson <i>et al.</i> (2020) <sup>261</sup>	

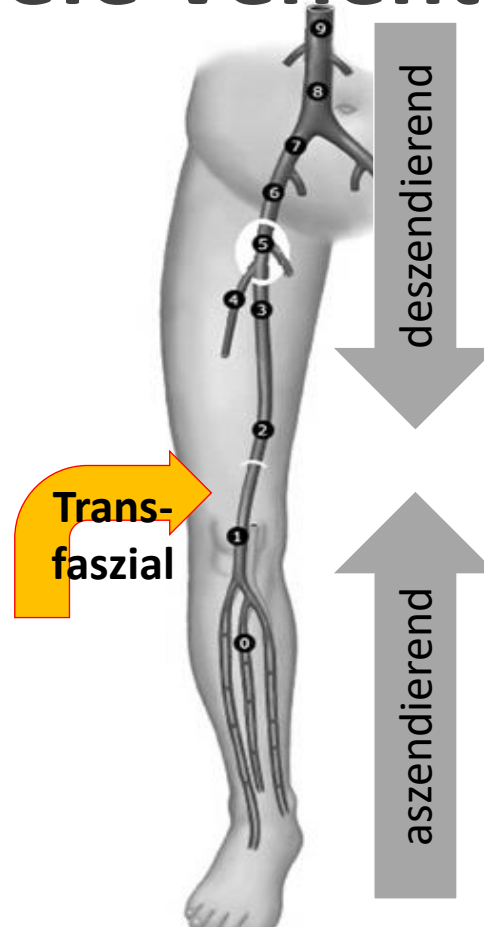
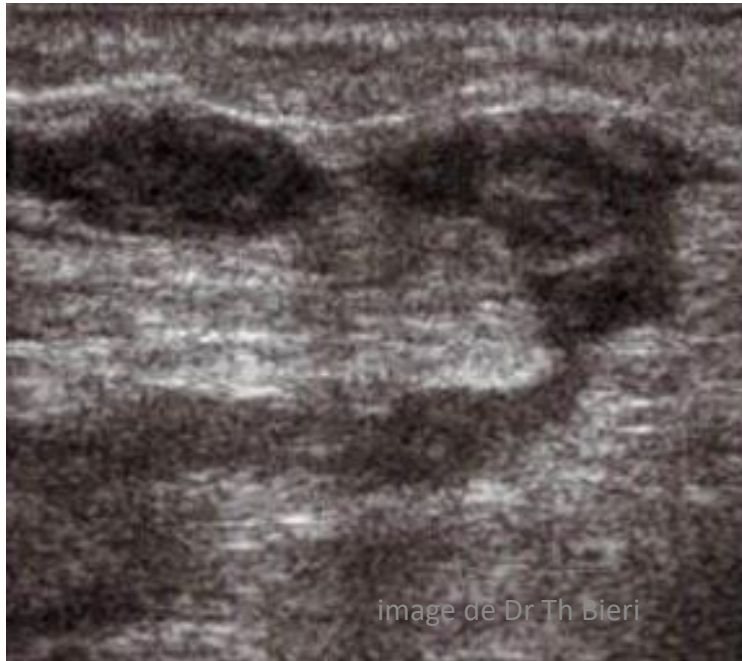
The 2023 Society for Vascular Surgery, American Venous Forum, and American Vein and Lymphatic Society clinical practice guidelines for the management of varicose veins of the lower extremities. Part II

*Endorsed by the Society of Interventional Radiology and the Society for Vascular Medicine*

10. Ablation of incompetent perforating veins		
Guidelines	Grade of recommendation	Quality of Evidence
10.1.1. For patients with varicose veins (CEAP class C2) who have significant, symptomatic axial reflux of the GSV or SSV, we <u>recommend against</u> treatment of incompetent perforating veins concomitant with initial ablation of the saphenous veins.	1 (strong)	C (low to very low)
10.1.2. For patients with varicose veins (CEAP class C2) who have significant, symptomatic axial reflux of the AAGSV or PAGSV, we suggest against treatment of incompetent perforating veins concomitant with initial ablation of the superficial truncal veins.	2 (weak)	C (low to very low)
Consensus statement		
10.2. <u>For patients with incompetent pathologic perforators associated with symptomatic residual, recurrent, and rarely primary varicosities, without associated saphenous incompetence, either open or endovascular techniques can be used to treat the perforator veins.</u>		

# Weitere wichtige Bedeutung der Perforansvenen?

## → Transfasziale tiefe Venenthrombose



Bei oberflächlicher Venenthrombose (OVT) auch tiefes Venensystem untersuchen!

- $\frac{1}{4}$  der Patienten mit OVT haben gleichzeitige TVT

Ultraschall-Risikofaktoren für gleichzeitige TVT

- Perforans Venen thrombosiert (OR 8.1) oder OVT <3cm vom sapheno-femorale Übergang (OR 3.3)

# Zusammenfassung

- Perforansvenen mit wichtiger Rolle v.a. bei fortgeschrittener CVI
- Perforansinsuffizienz in der Duplexuntersuchung
  - Reflux (in der Diastole)
  - Vergrößerter Durchmesser
  - Unterscheidung **Exit-PV** und **Re-entry-PV**
- PV-Therapie nur bei fortgeschrittener CVI indiziert, mit minimal-invasiven Methoden
- Bei oberflächlichen Venenthrombose an transfasziale Ausdehnung denken → Duplex!

