

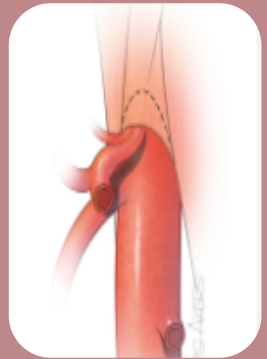
VASKULÄRE KOMPRESSIONSSYNDROME



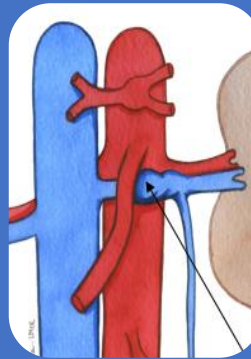
Dr. Katja Stürzebecher
Oberärztin Angiologie



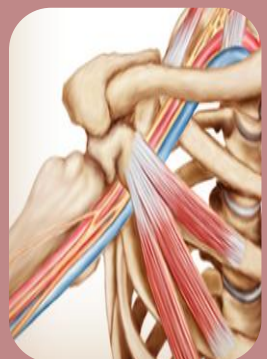
Anatomisch bedingte Einengungen von
Gefäßen durch benachbarte Strukturen



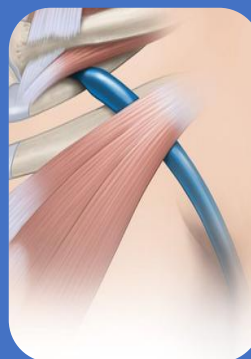
Medianes
Arcuatum-
Ligament-Syndrom



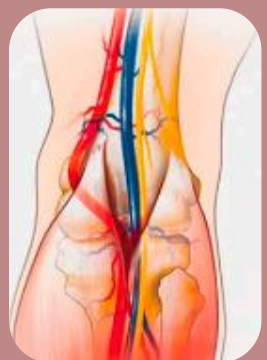Nussknacker-
Syndrom



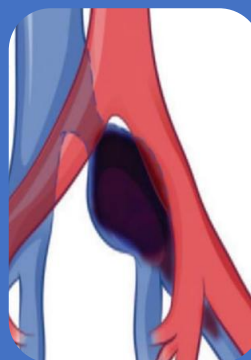
Thoracic outlet
Syndrom



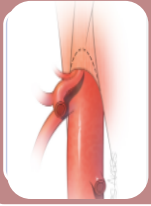
Thoracic inlet
Syndrom



Popliteales
Entrapment

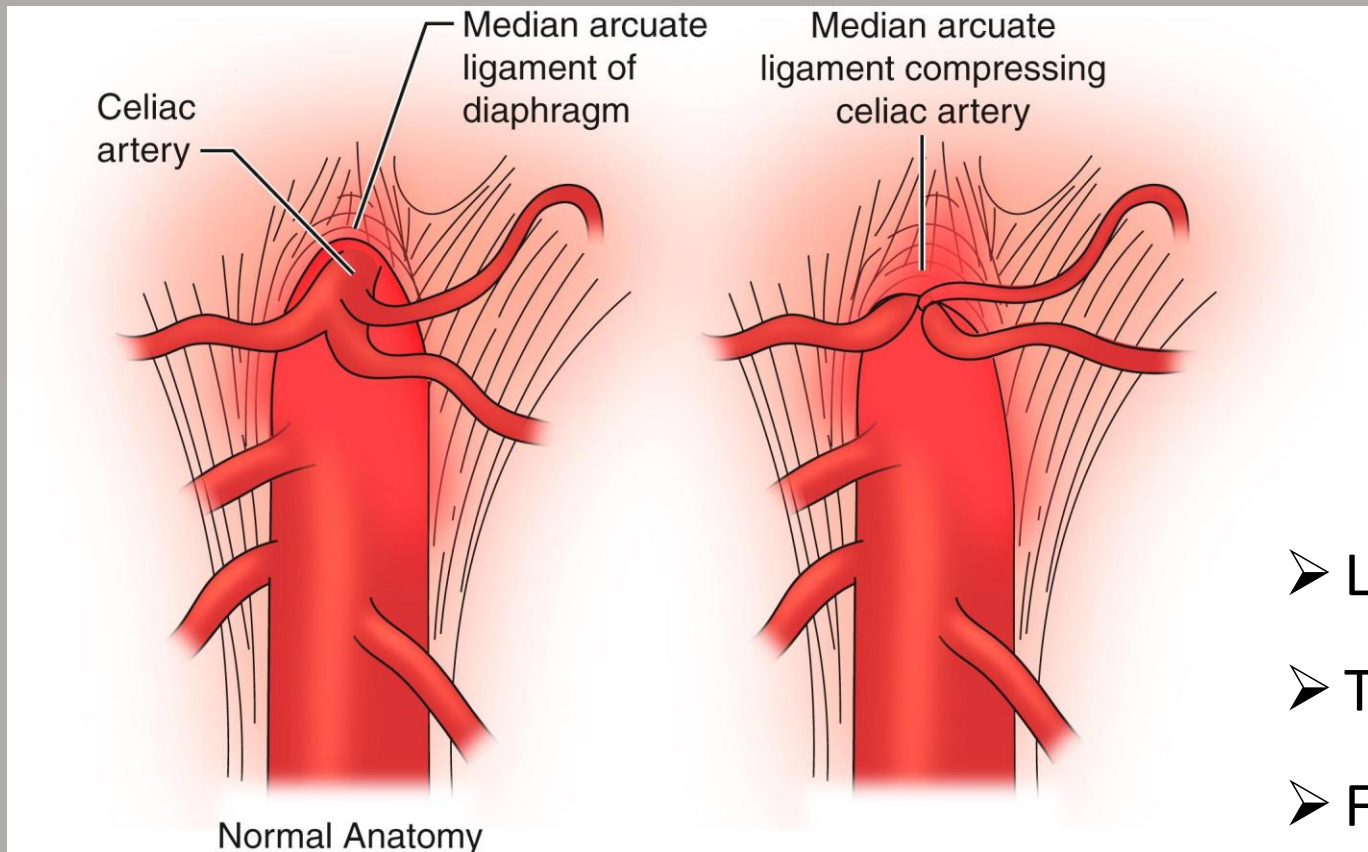


May-Thurner

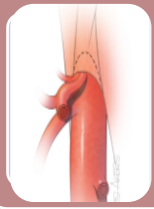


Medianes Arcuatum-Ligament-Syndrom

= Einengung des Truncus coeliacus
resp. Reizung des Plexus coeliacus

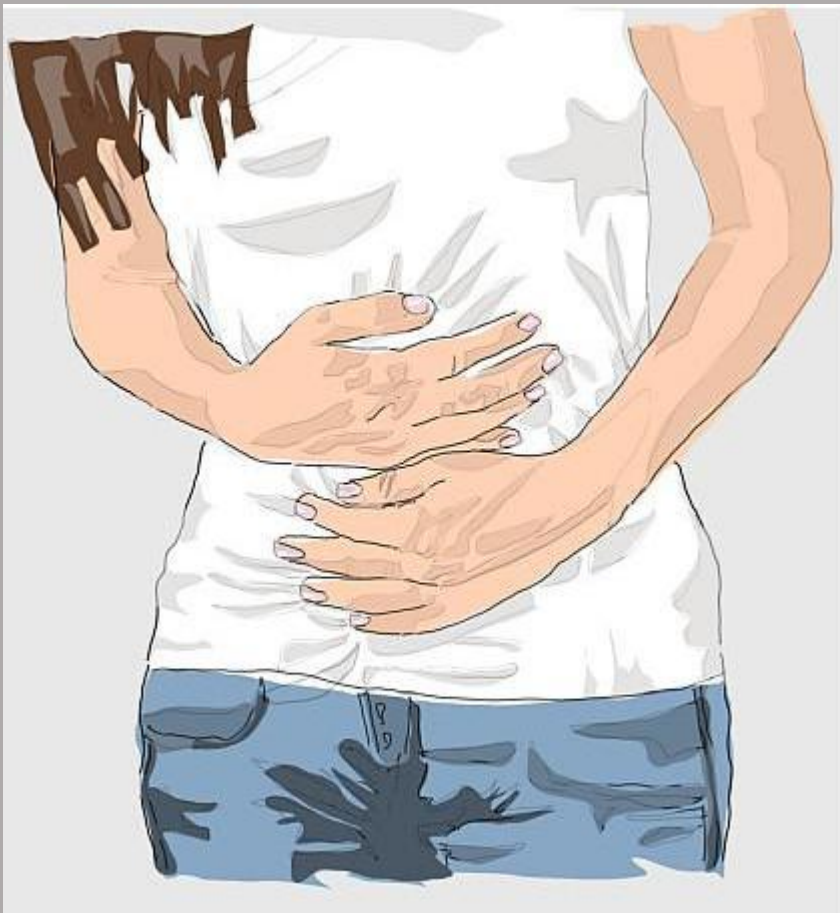

- Ligament zu caudal?
- Truncus zu cranial?
- Fibröse Bänder? ...



Medianes Arcuatum-Ligament-Syndrom

Schlanke Frau



Postprandiale Schmerzen

Diarrhoe

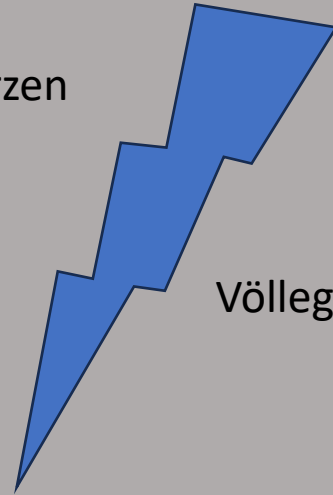
Oberbauchschmerzen

Meteorismus

Gewichtsverlust

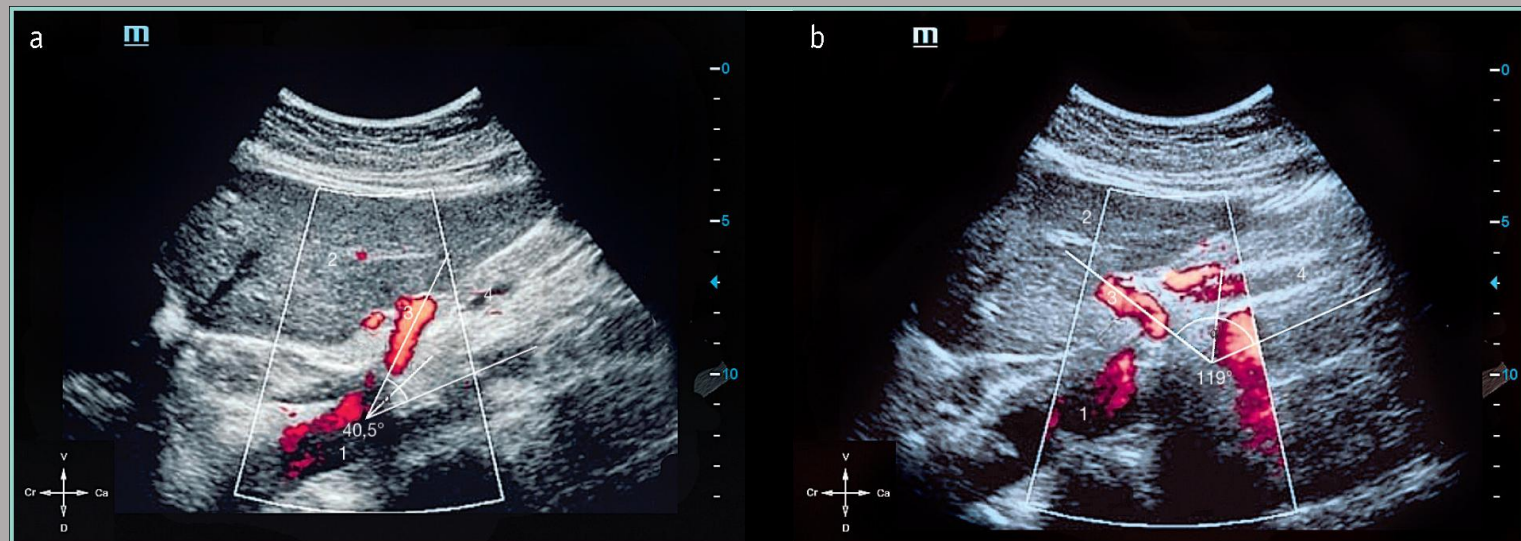
Völlegefühl

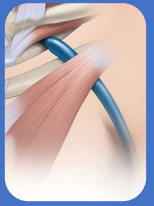Nausea



Duplexsonografie

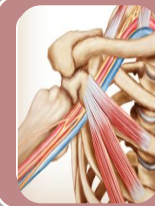- Zunahme der PSV in Expiration $\geq 350\text{cm/s}$
- Deflexionswinkel +



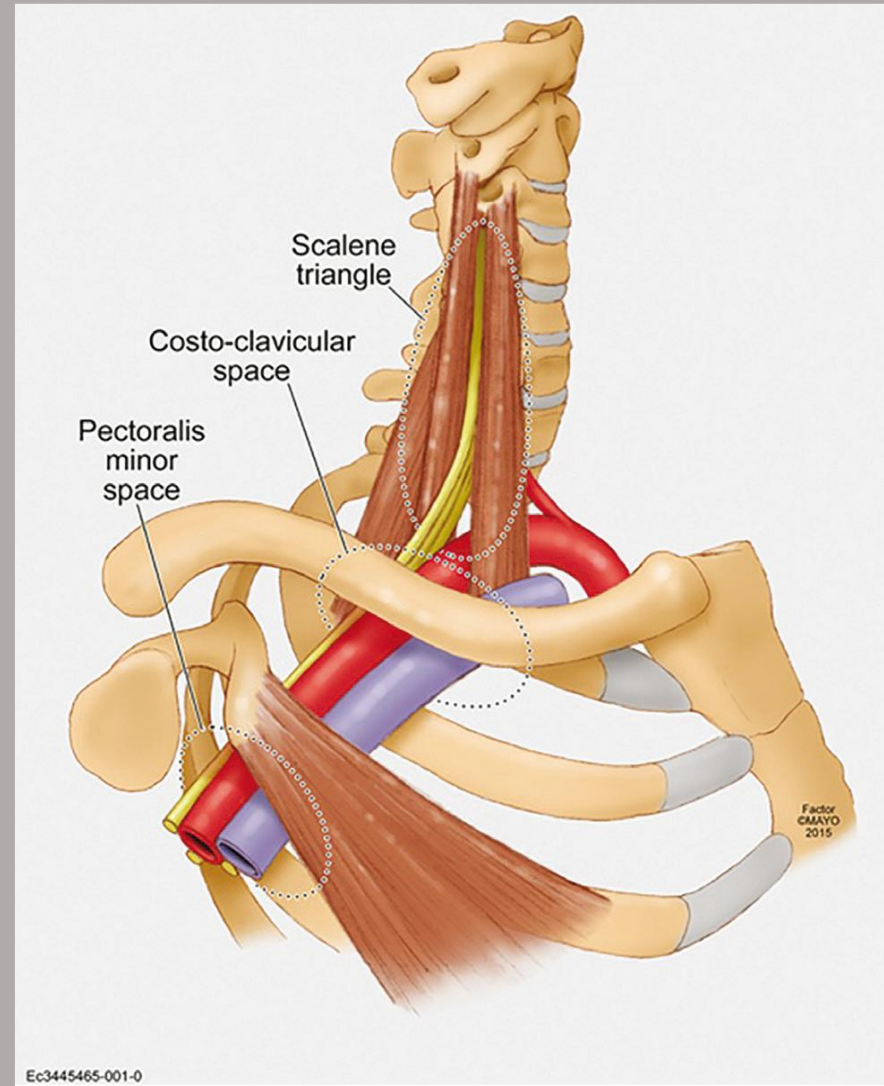


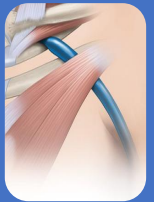
Thoracic inlet Syndrom

= Einengung V/A. subclavia, Plexus
brachialis im Bereich der oberen
Thoraxapertur

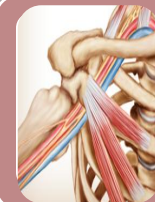

Thoracic outlet Syndrom

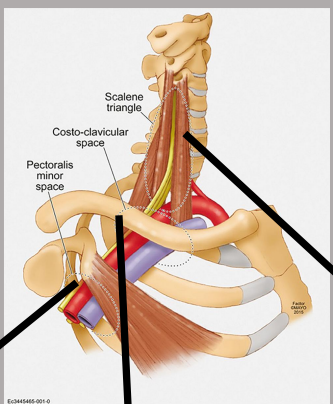




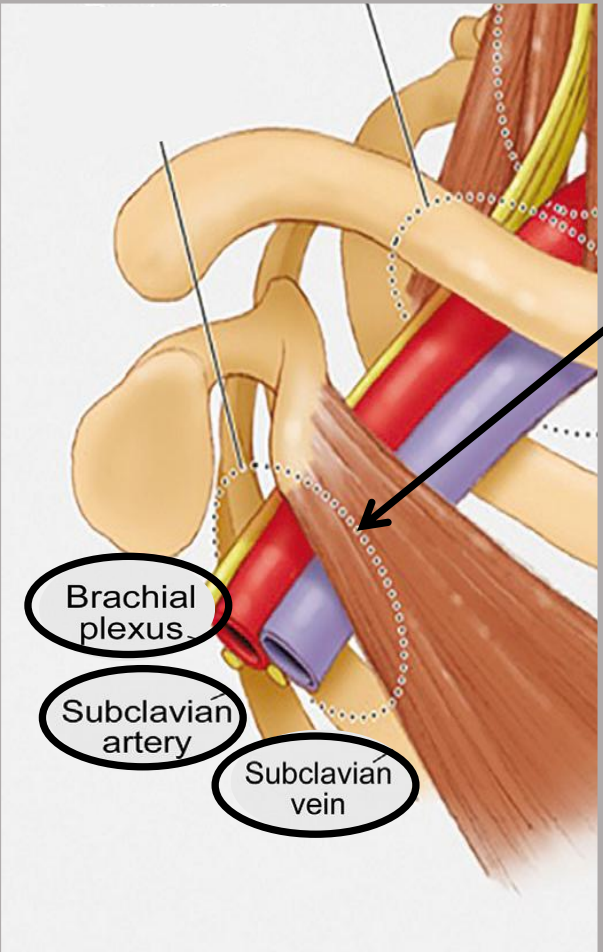
Thoracic inlet Syndrom



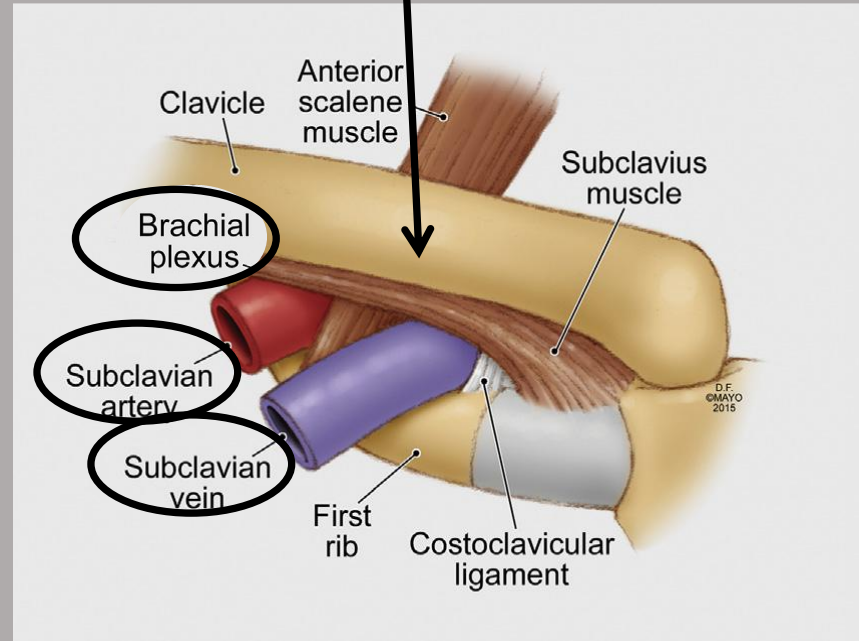
Toracic outlet Syndrom



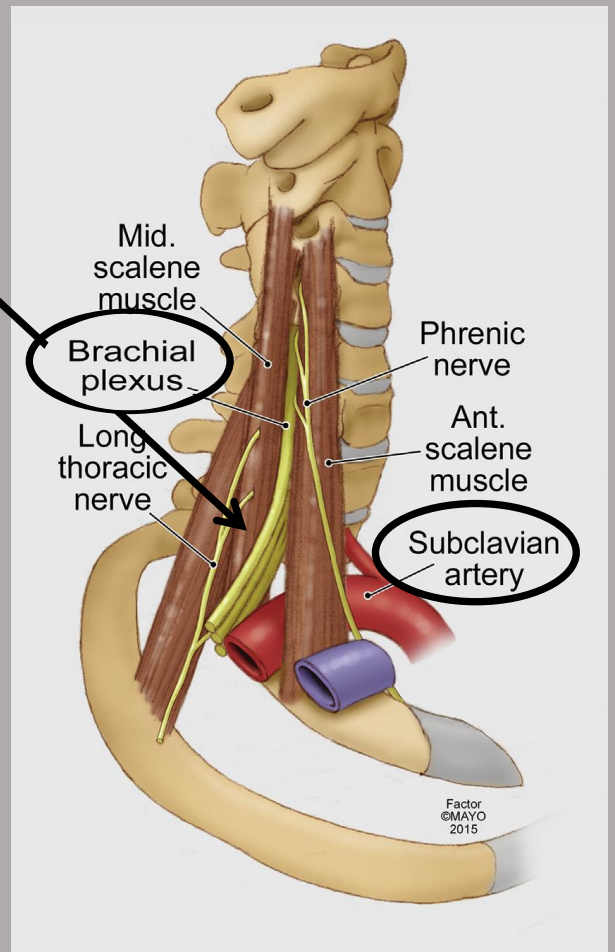
Pectoralis Minor Raum



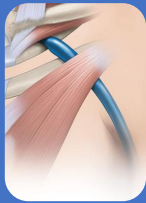
Costoclavikularraum



Skalenuslücke



Factor ©MAYO 2015

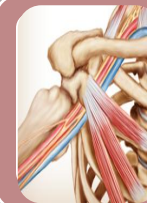

Thoracic inlet Syndrom



Venöses TIS 3-5%

- Schwellung, Zyanose Arm/Hand
- Kollateralbildung
- Armvenenthrombose

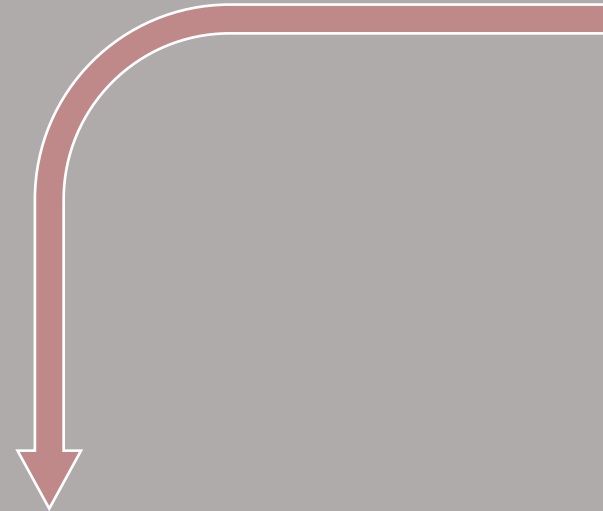


Toracic outlet Syndrom



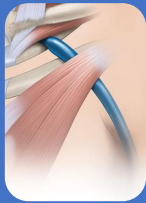
Arteriellles TOS 1%

- Claudikatio/Ischämien
Hand u./oder Finger



Neurogenes TOS 95%

- Häufig bilateral
- Parästhesien
- Schmerzen, Verspannung
- z.T. nachts schlimmer
- Schwäche/feinmotorische Störungen



Thoracic inlet Syndrom

Venöses TIS 3-5%

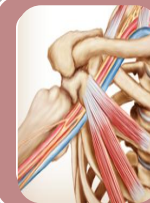- Schwellung, Zyanose
Arm/Hand
- Kollateralbildung
- Armvenenthrombose

Neurogenes TOS 95%

- Häufig bilateral
- Parästhesien
- Schmerzen, Verspannung
- z.T. nachts schlimmer
- Schwäche/feinmotorische
Störungen

Arteriell TOS 1%

- Claudikatio/Ischämien
Hand u./oder Finger

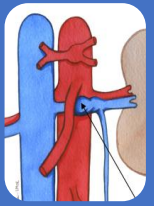


Toracic outlet Syndrom

Diagnostik ist schwierig

ABER

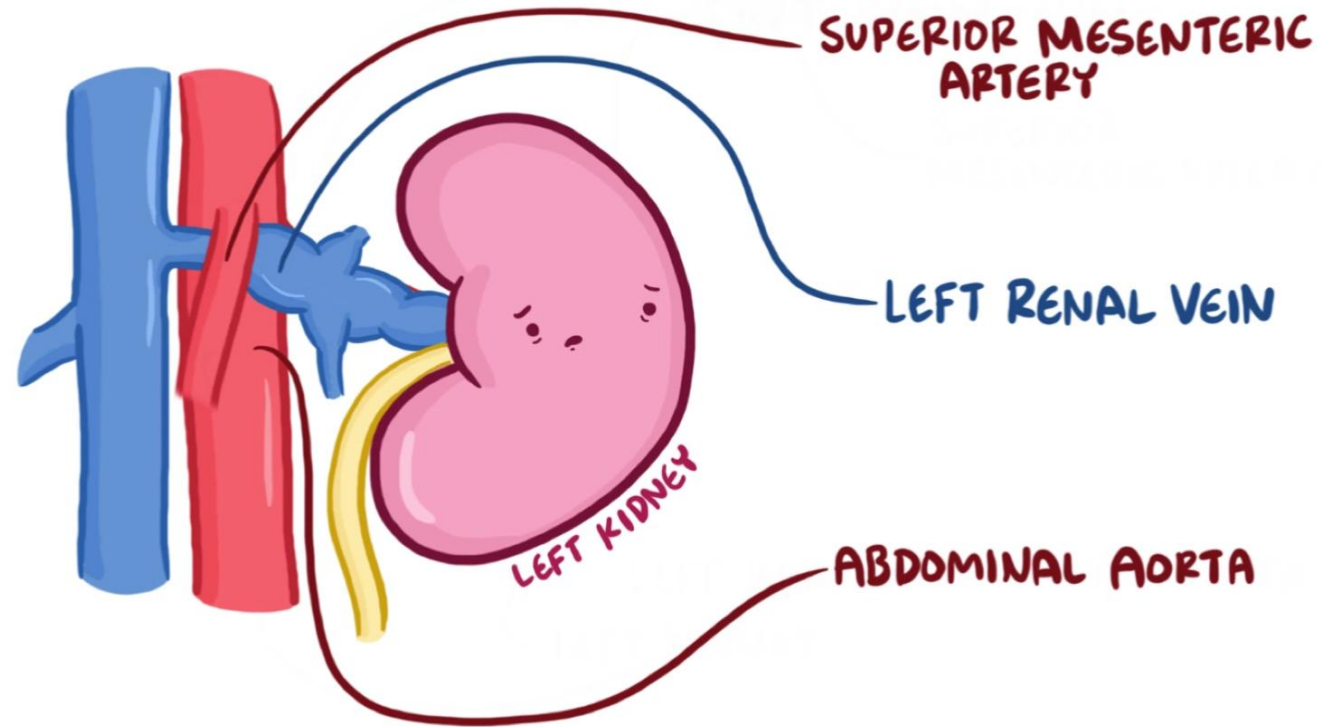
Untersuchung in
Provokationsstellung, sowohl
klinisch als auch
duplexsonografisch!

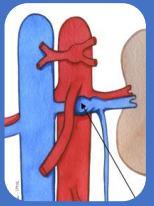


Nussknacker-Syndrom

= Einengung linke Nierenvene zwischen Aorta und AMS

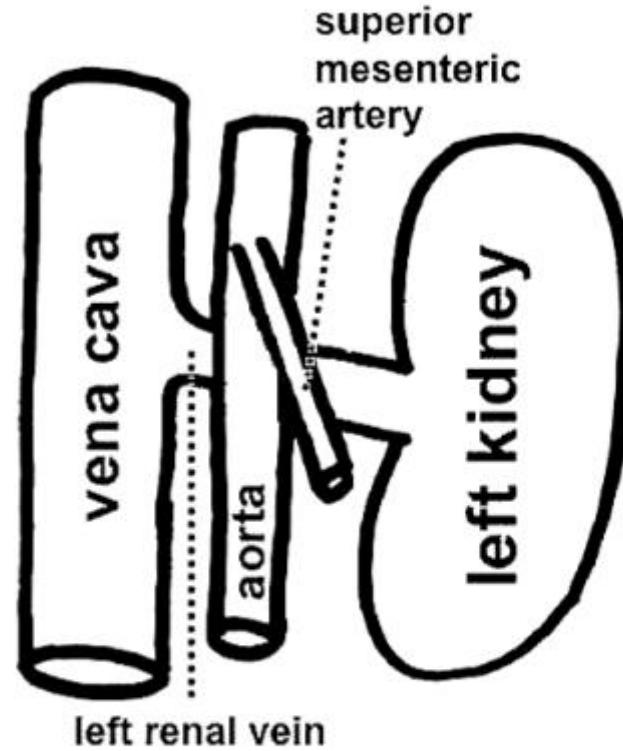
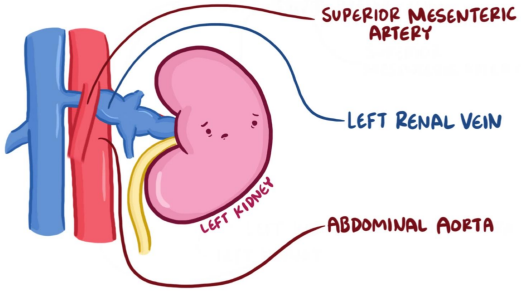
RENAL NUTCRACKER SYNDROME





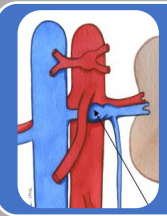
Nussknacker-Syndrom

RENAL NUTCRACKER SYNDROME



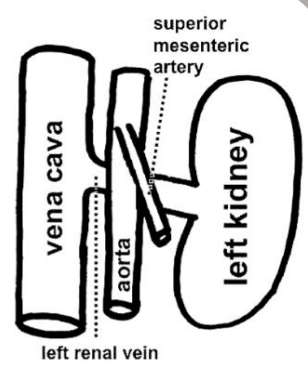
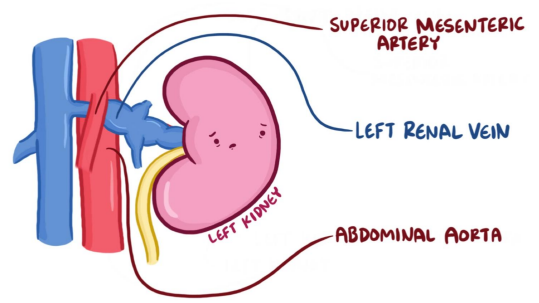
Retro-Aortic Left Renal Vein

Retro-Aortic (= Posterior)
Entrapment



Nussknacker-Syndrom

RENAL NUTCRACKER SYNDROME



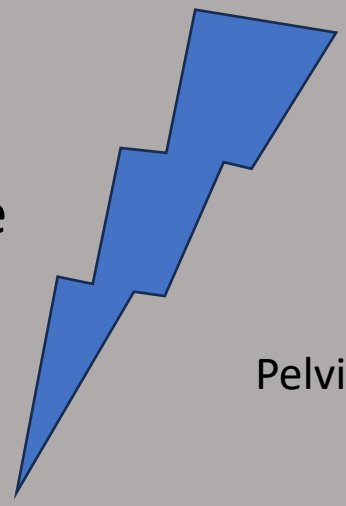
Retro-Aortic Left Renal Vein
Retro-Aortic (= Posterior) Entrapment

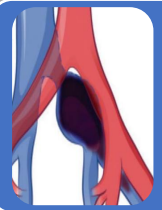Linke Flankenschmerzen

Hämaturie

Proteinurie

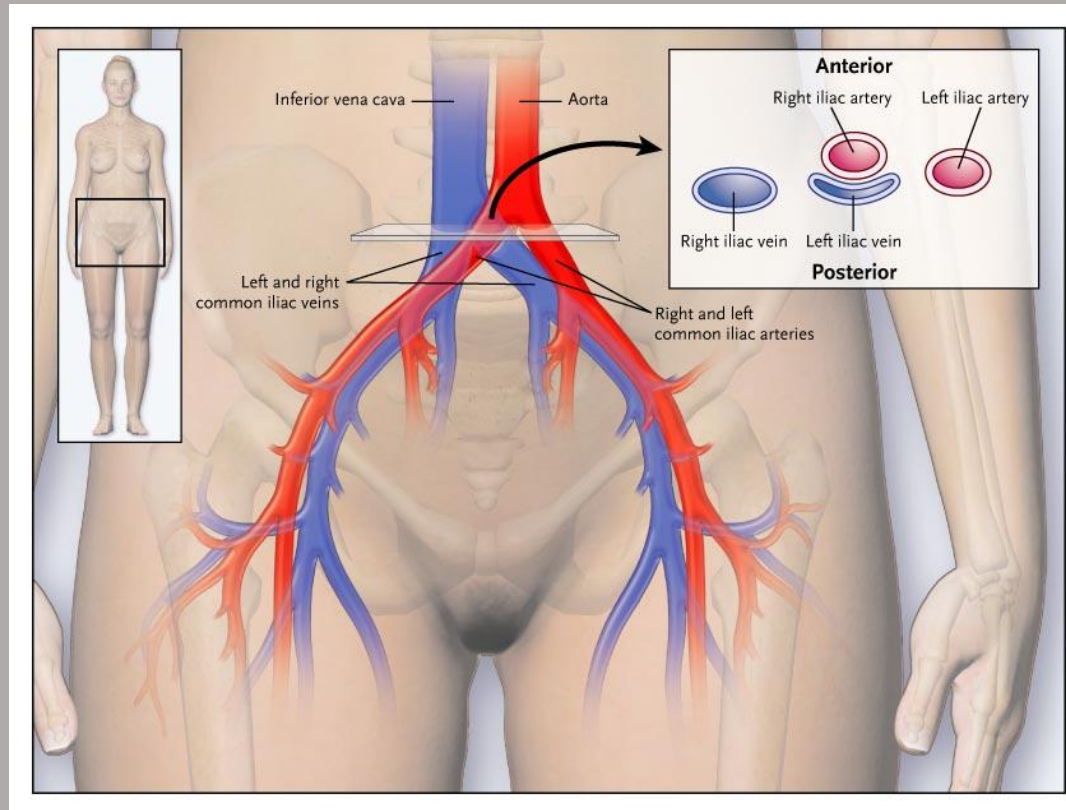
Pelvic congestion

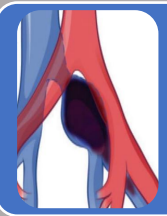



May-Thurner

= Kompression linke V. iliaca
communis unter der rechten A. iliaca
communis





May-Thurner

➤ ♂ < ♀

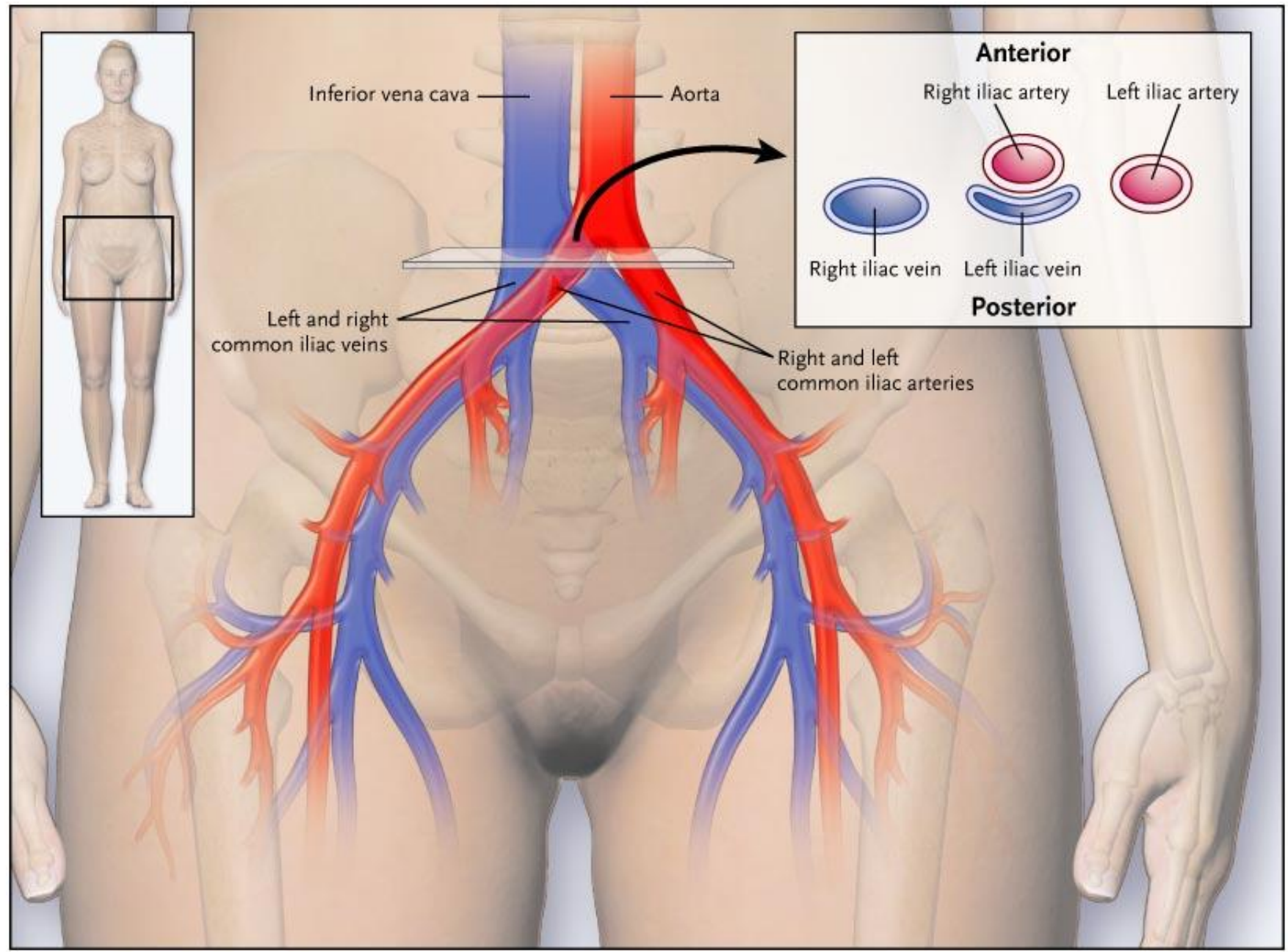
➤ Beckenvenenthrombose


➤ Schwellung

➤ Schwere

➤ Schmerzen

➤ Venöse Claudikatio





Popliteales
Entrapment

= Einklemmung der A. poplitea

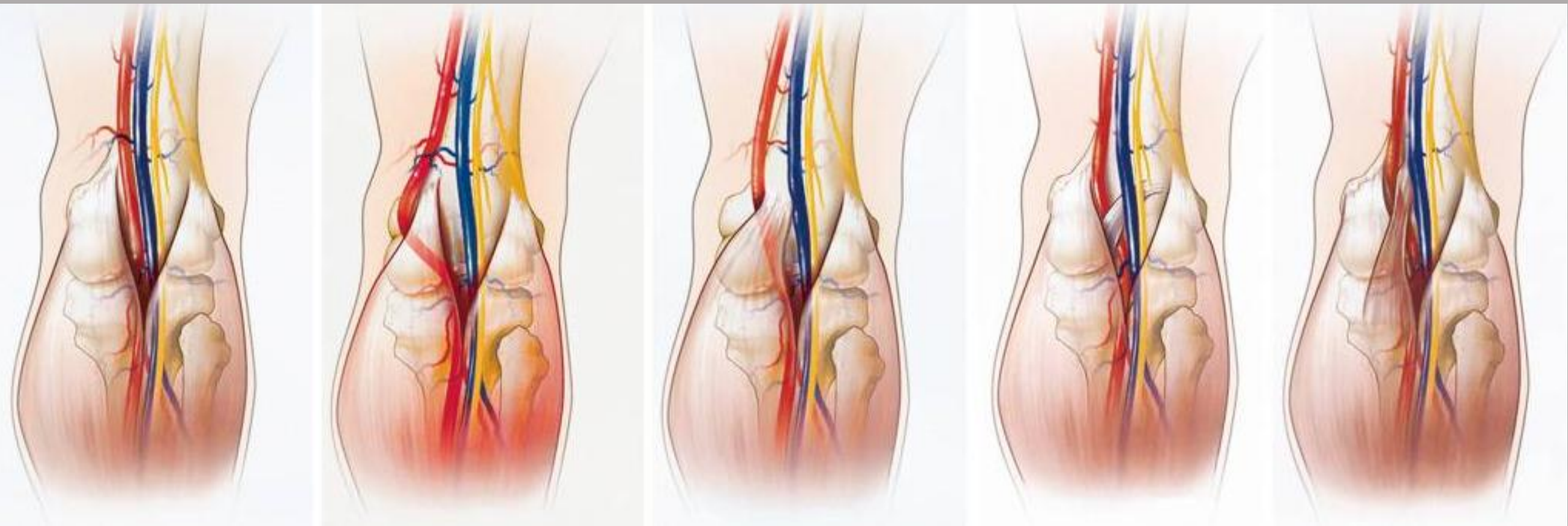
normal

Typ I

Typ II

Typ III

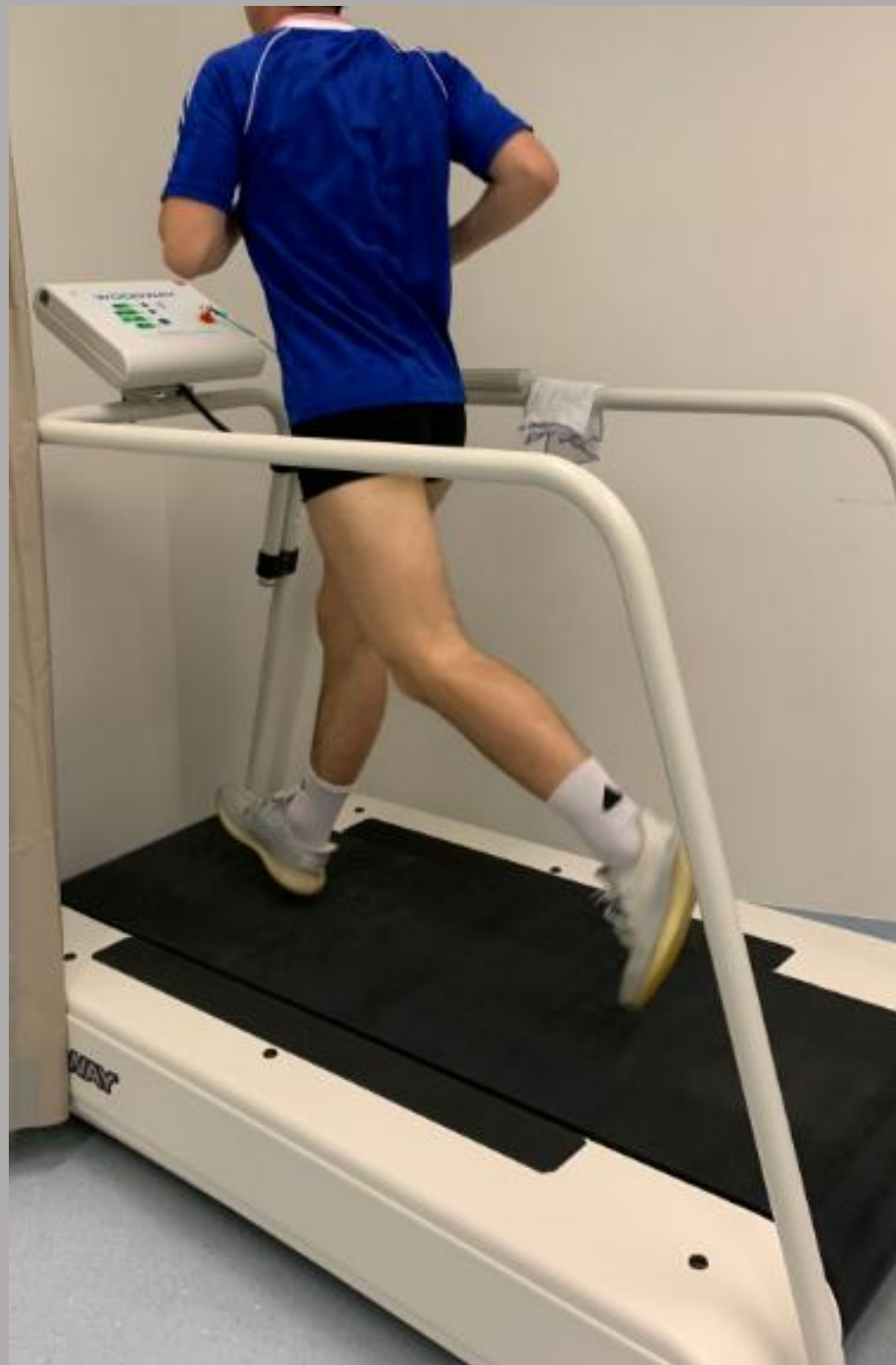Typ IV

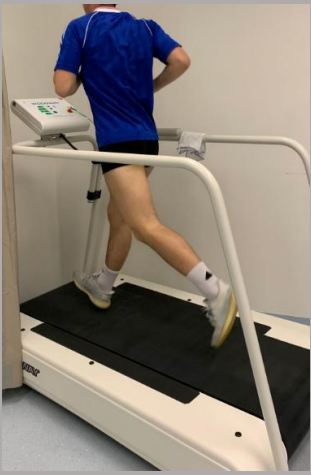

medial

lateral

➤ Junge sportliche Männer

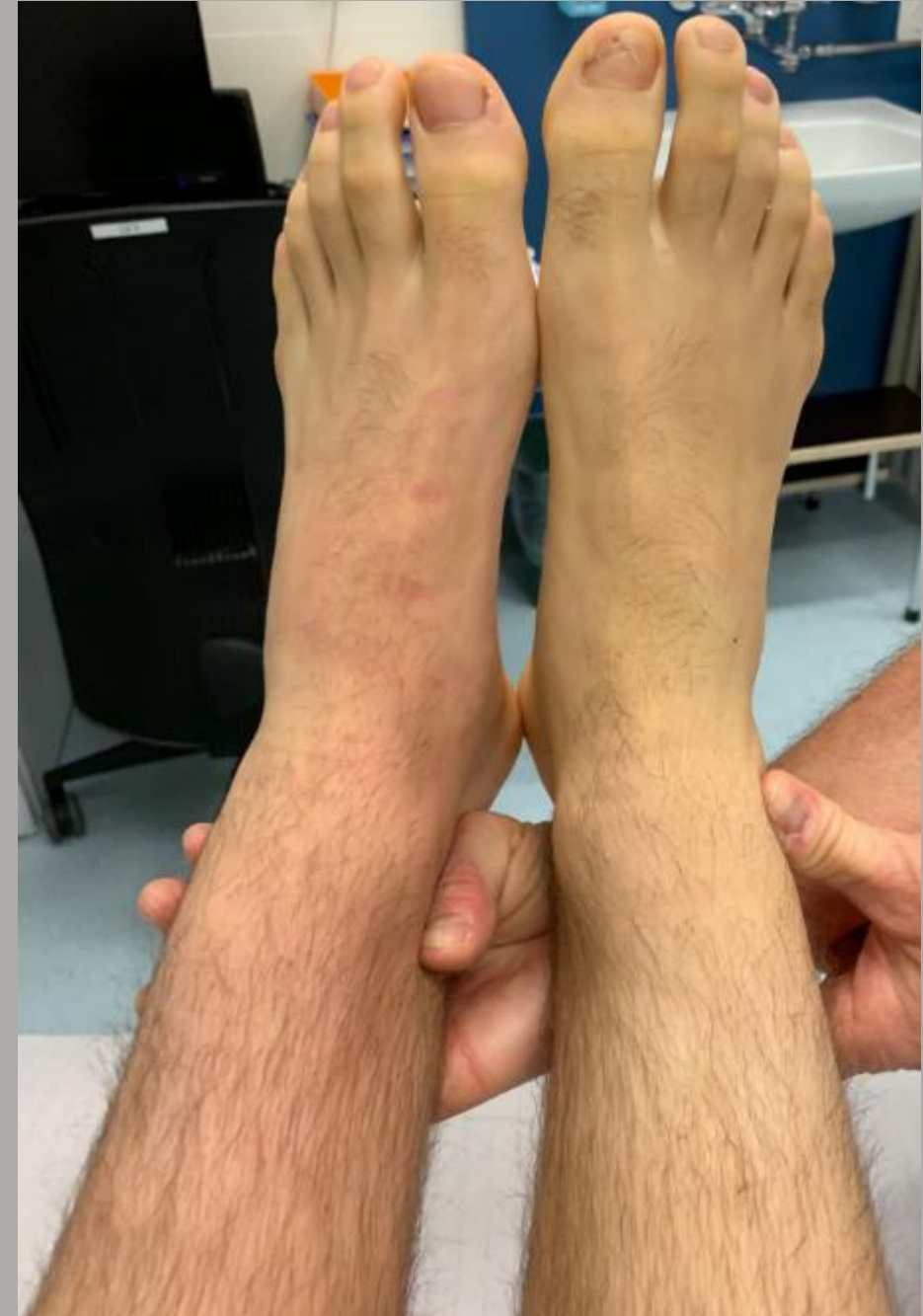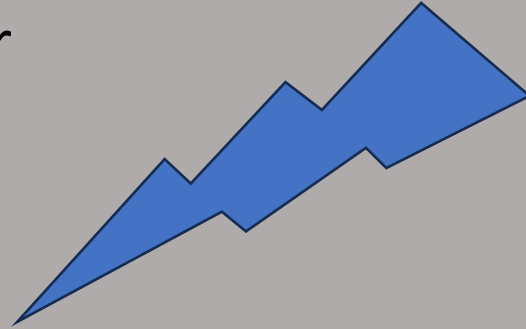


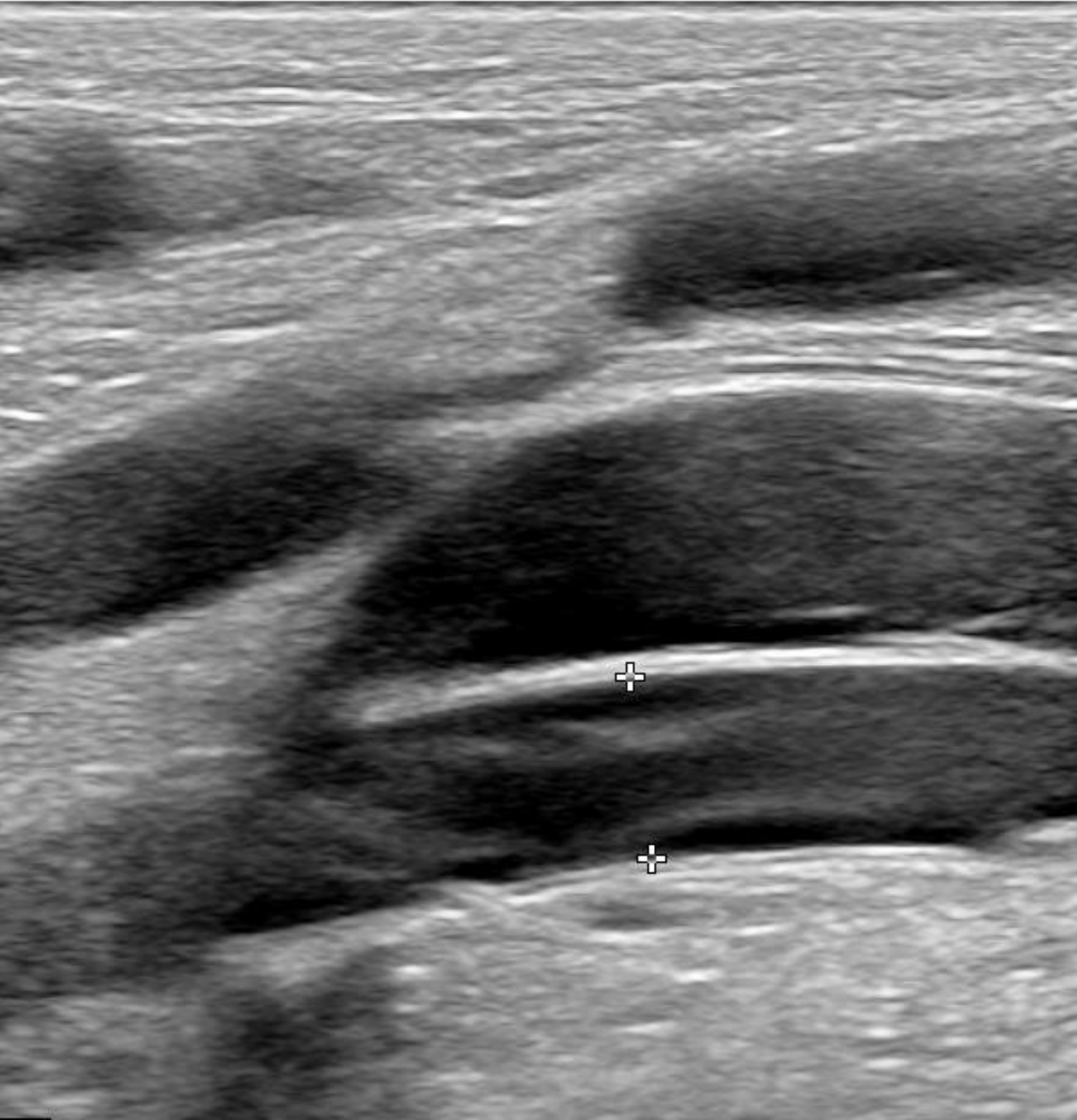


➤ Junge sportliche Männer

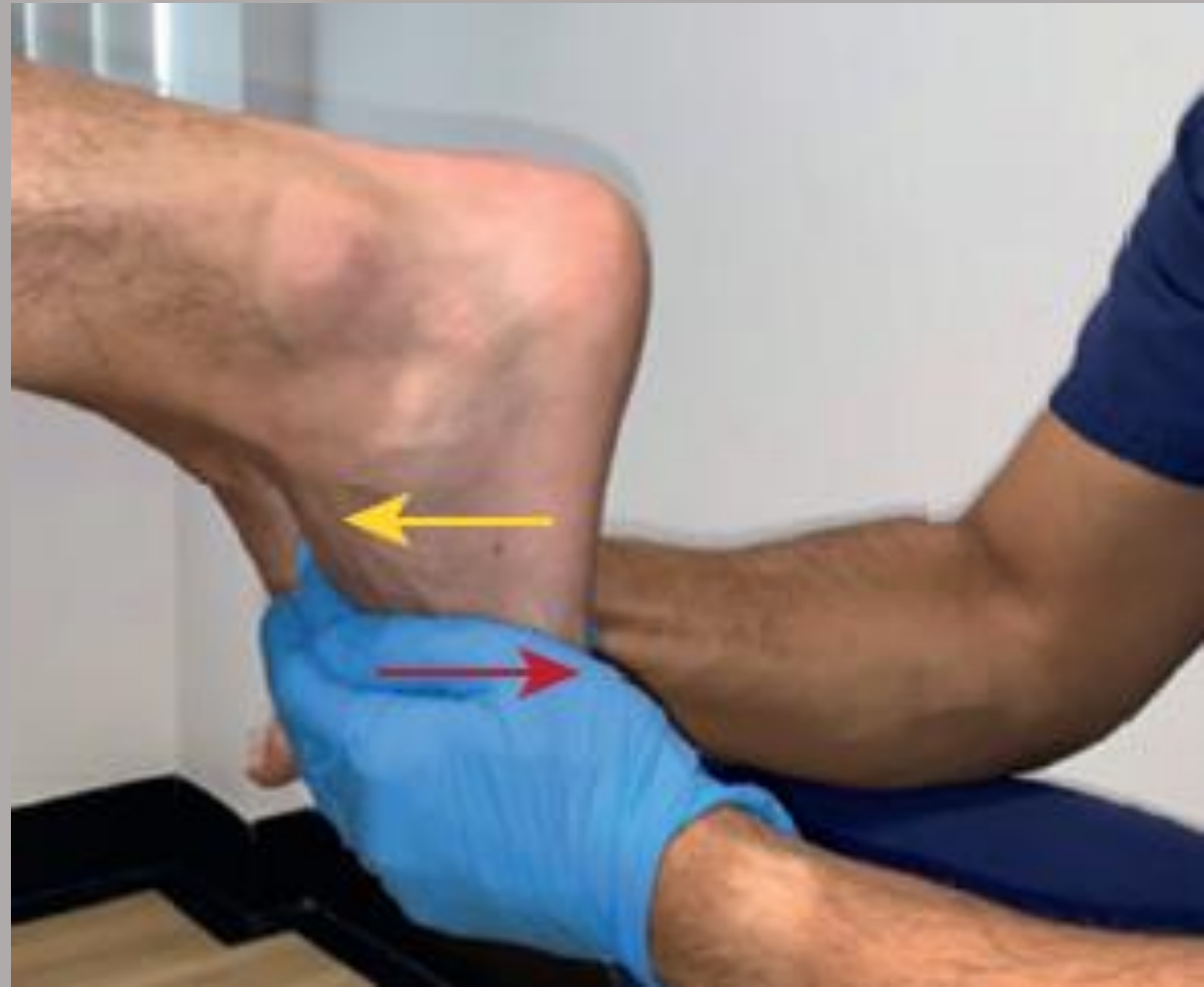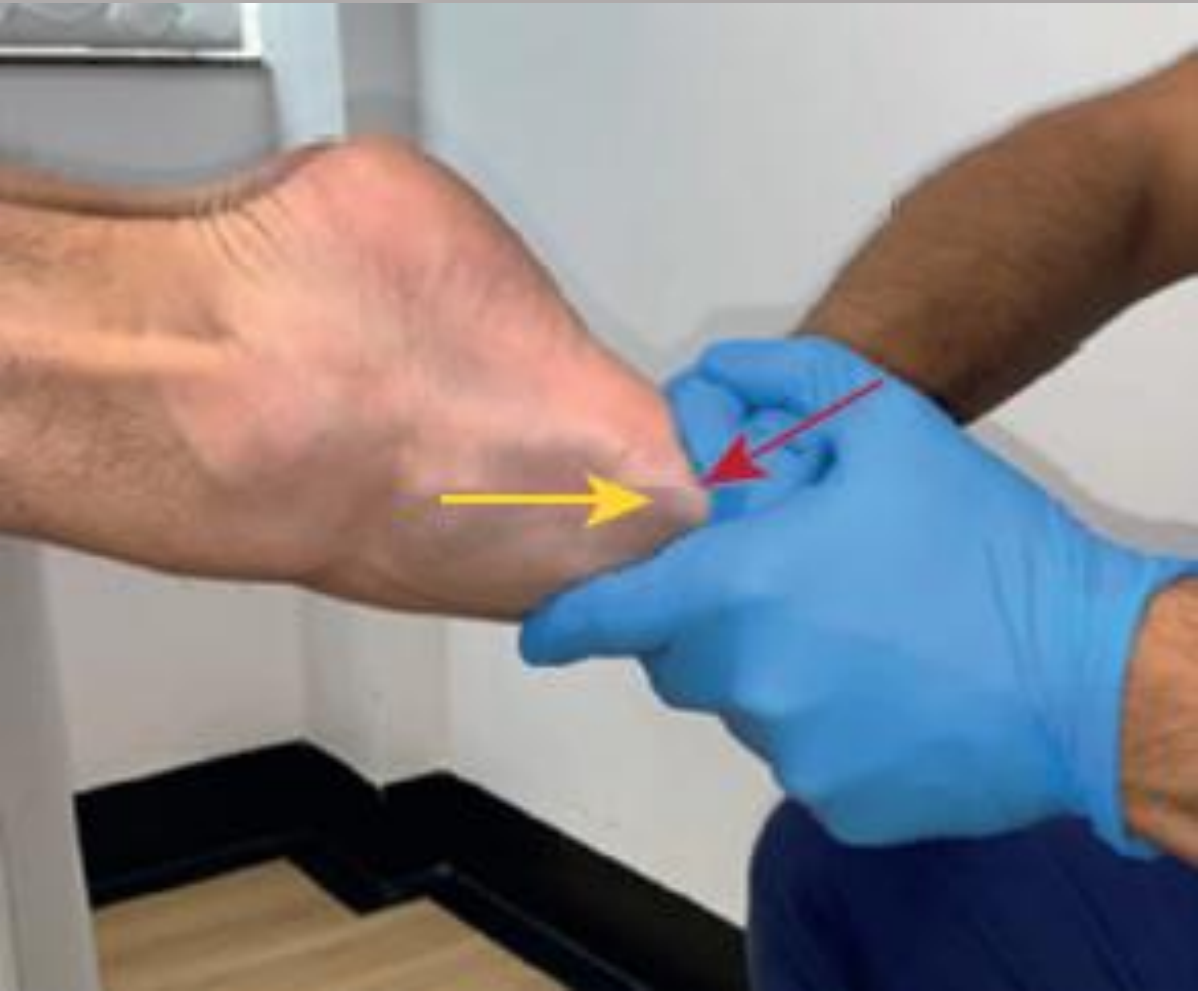➤ Claudikatio intermittens

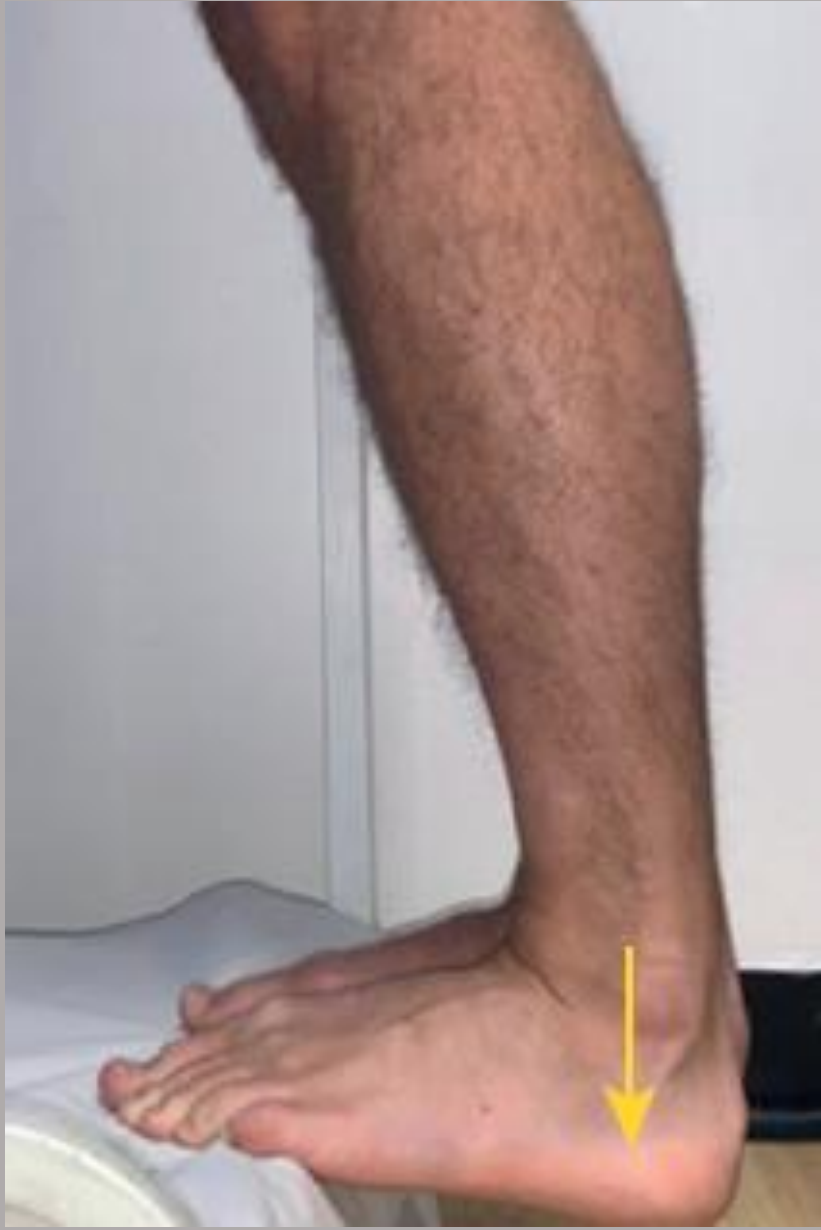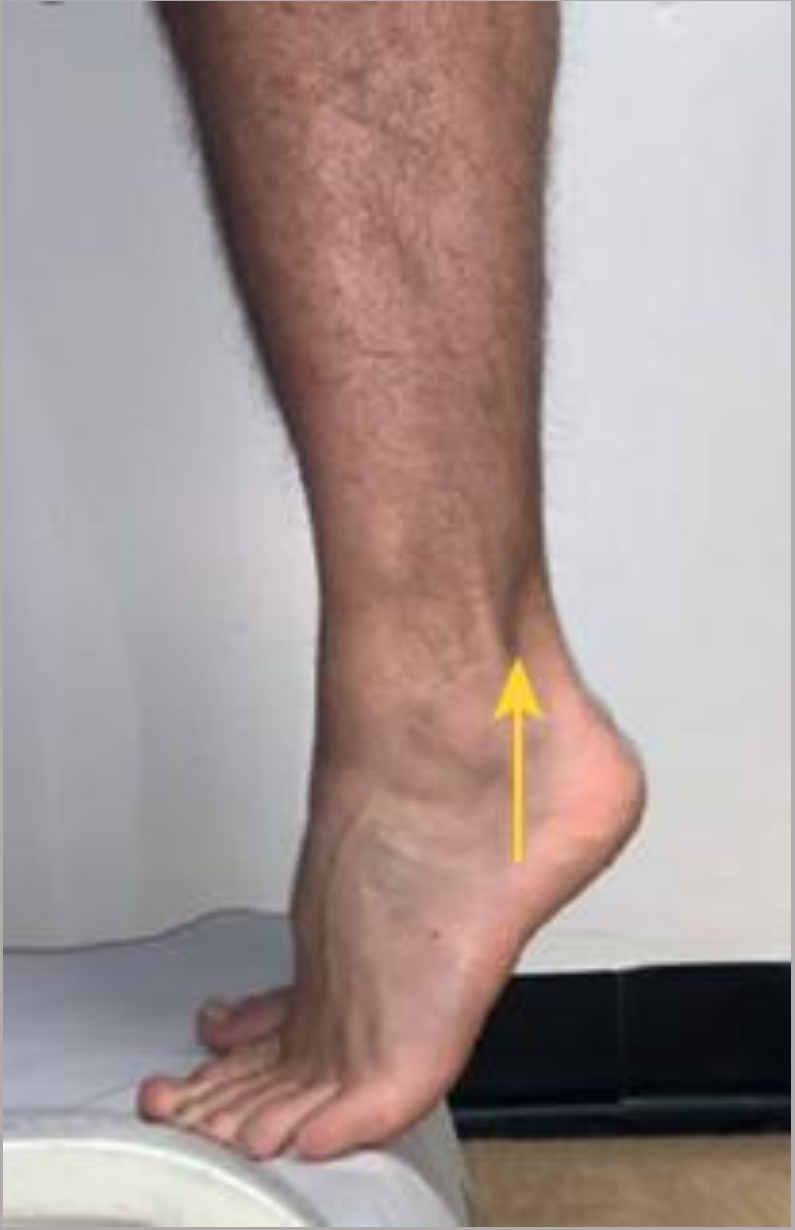➤ Ischämische Beschwerden bei Belastung

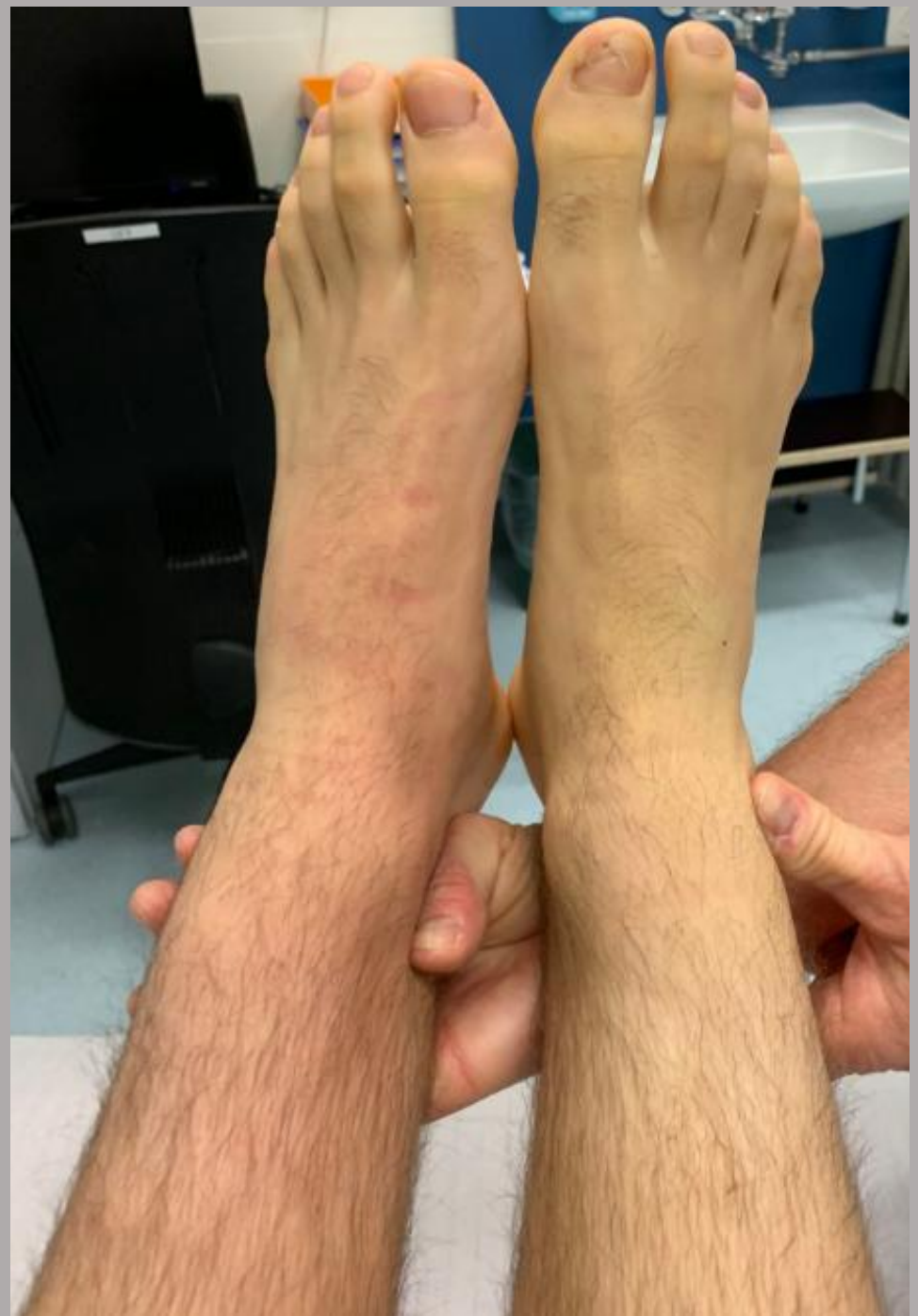
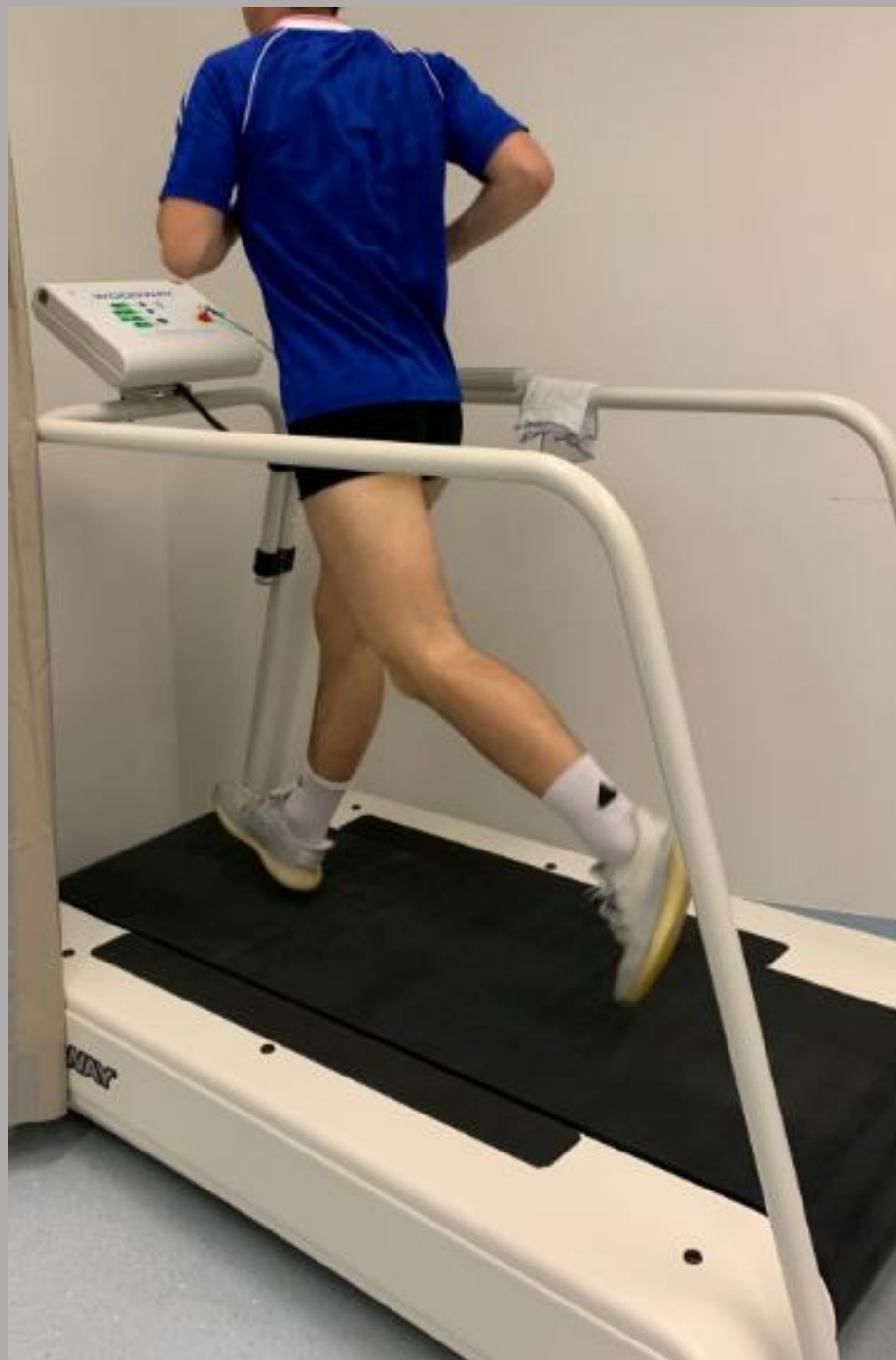
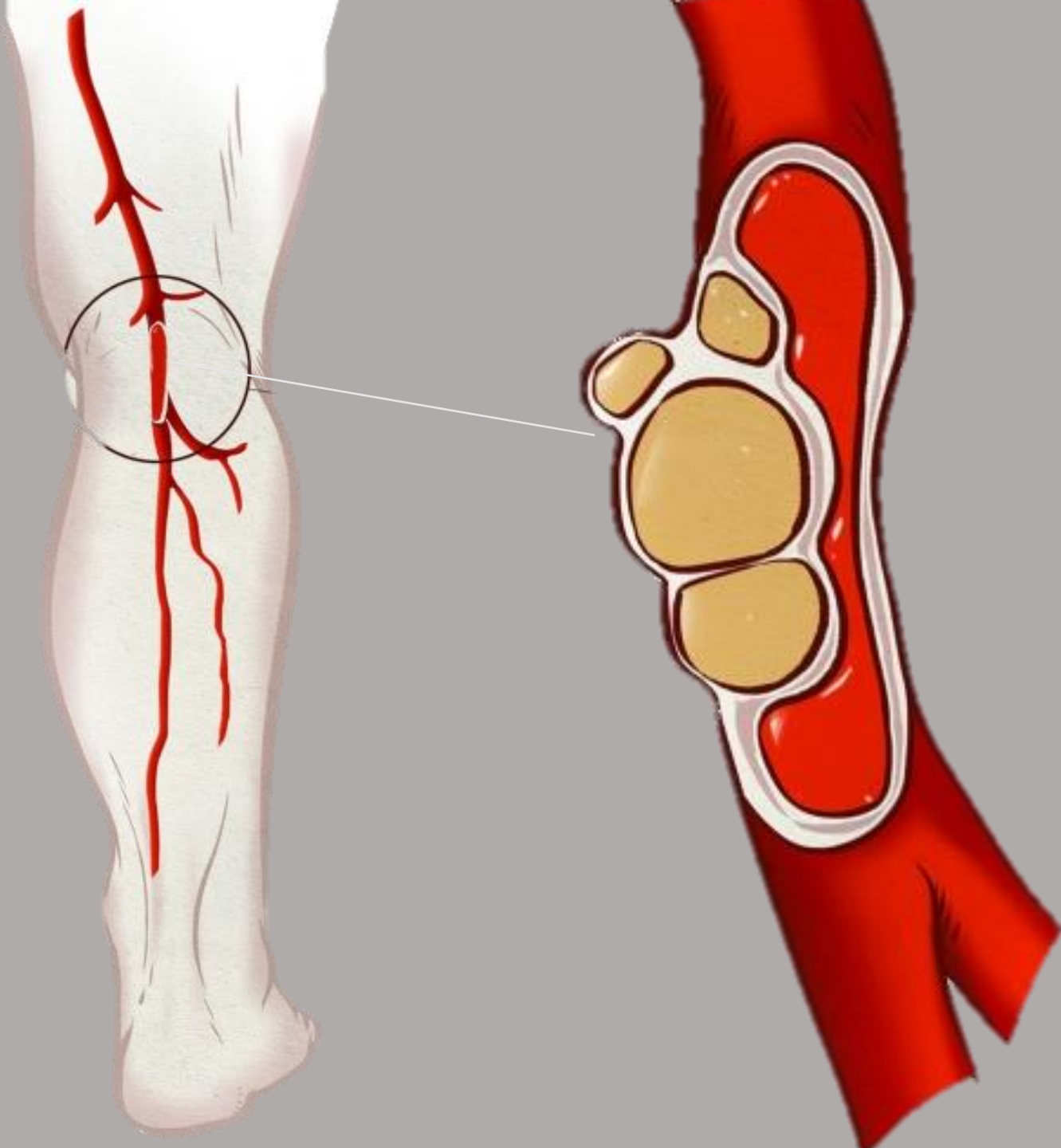


Bauchlage



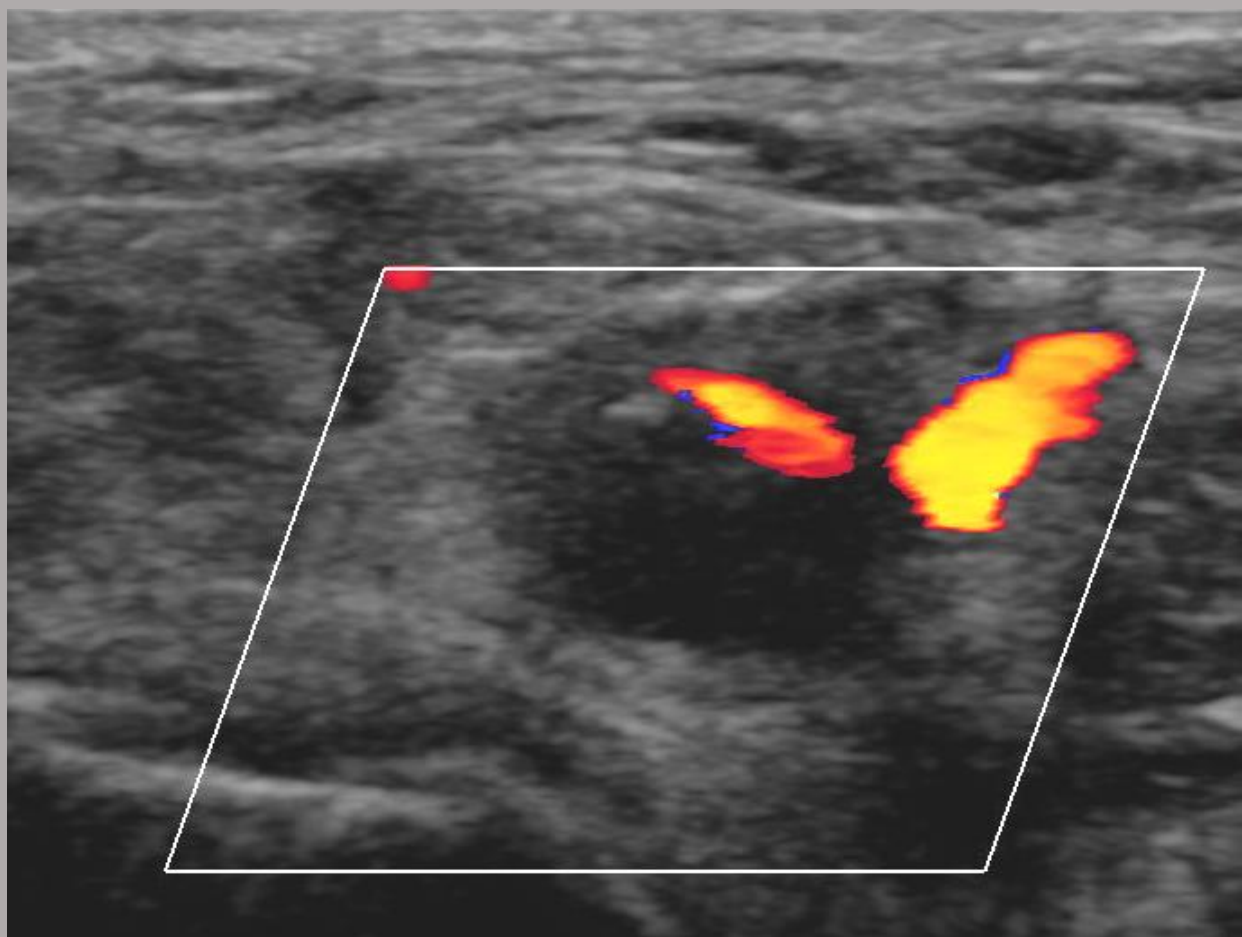
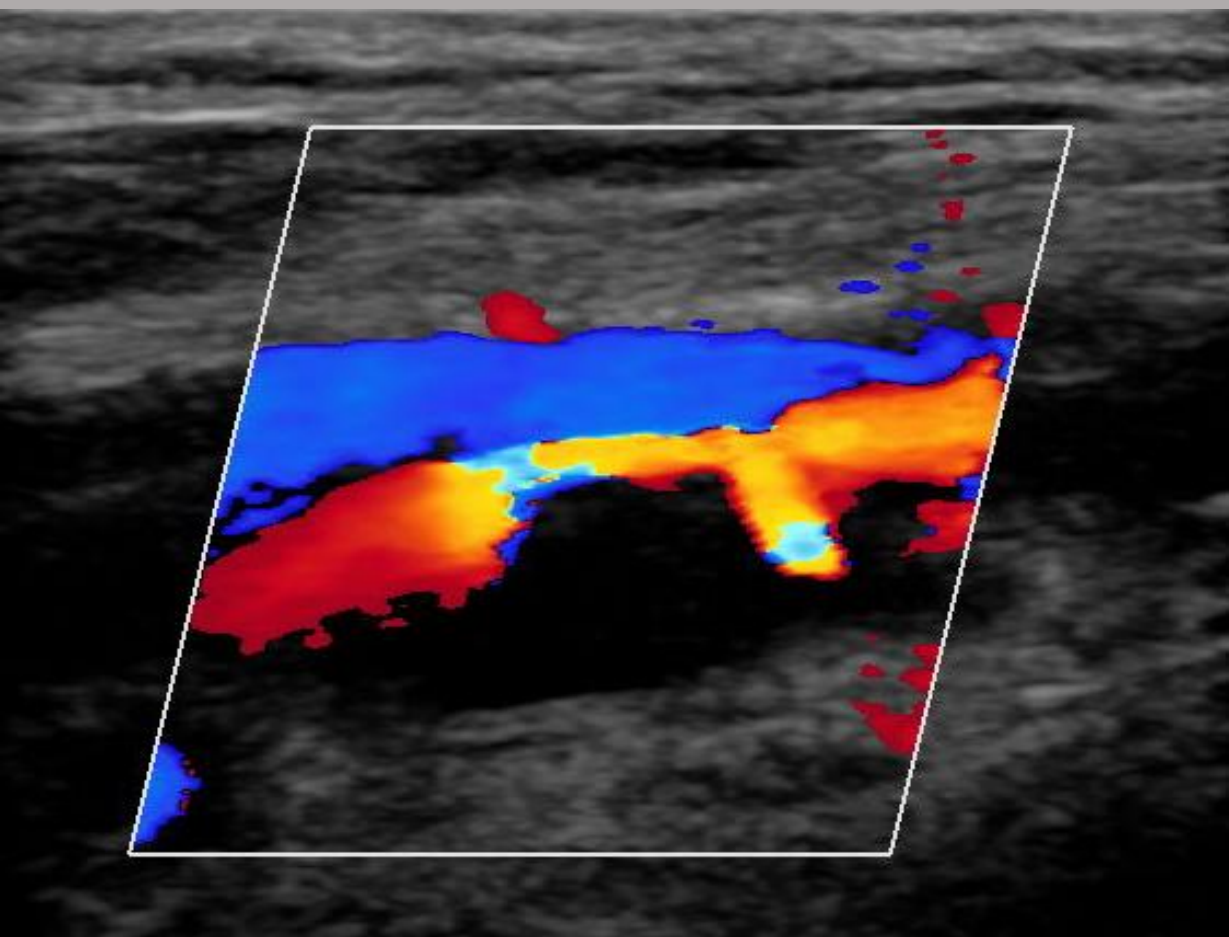






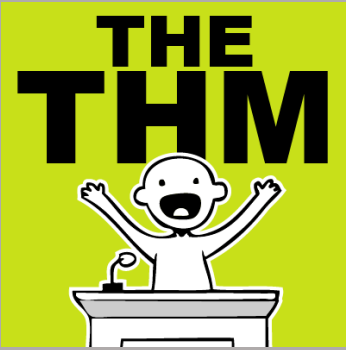Zystische
Adventitiadegeneration

= Einklemmung der A. poplitea
durch Zysten



THE THM





- ✓ Daran denken...Gefäßprobleme auch bei Sportlern und jungen Patienten
- ✓ Physiologisch oder pathologisch?
- ✓ Untersuchung in Provokation

Vielen Dank für
Ihre
Aufmerksamkeit!

Fragen?

